

CASE REPORT

Primary Small Cell Neuroendocrine Carcinoma of the Kidney: A Case Report

Rongbo Xue, Haifeng Wang, Ning Li, Yinglong Huang, Yi-gang Zuo*

Department of Urology, The Second Affiliated Hospital of Kunming Medical University, Kunming 650101, China

Abstract: The cases of primary small cell neuroendocrine carcinoma (SCNEC) of the kidney are rarely known in the clinical setting, and our understanding on this cancer is limited. We recently found a case of primary SCNEC of the kidney in our clinic. The clinical manifestation from the process of diagnosis to the treatment of this case was described in this report, enabling further understanding of cancer.

Keywords: Renal small cell carcinoma, Neuroendocrine carcinoma, Immunohistochemistry, Prognosis

1 Introduction

The cases of primary small cell neuroendocrine carcinoma (SCNEC) of the kidney are considered very rare in the clinical setting. Its malignancy degree is very high, and the efficacy of surgical treatment on this form of carcinoma is poor. Post-operative adjuvant radiotherapy or chemotherapy is not effective, so the treatment of SCNEC becomes more difficult. Our understanding on SCNEC is limited to case reports, and the research on this form of carcinoma is also limited.

In this case report, the diagnosis, treatment, and prognosis of SCNEC were comprehensively analyzed. This report aims to provide the case data of SCNEC to the medical and scientific communities, as to allow a deeper understanding of SCNEC. In addition, the goals of this case report include optimizing the diagnosis and treatment of SCNEC and improving the prognosis of SCNEC. Thus, this report provides a basic understanding of SCNEC detection and treatment that could be useful for future reference.

2 Case report

2.1 Patient examination

A 37-year-old male was admitted to the hospital on the account of “discovery of space-occupying lesions in the left kidney for a week.” The subject has no special medical history in the past.

Physical examination on the subject revealed soft abdomen and left mid-upper abdomen with a palpable mass which is tough, mobile, and unclear in size and boundary. The subject felt no pinching pain in the bilateral kidney regions. There were no abnormalities in an array of tests involving the patient’s blood, urine, liver function, kidney function, electrolyte, and tumor markers.

The subject underwent left inferior pole exploration, and the B-mode ultrasonography uncovered a hypoechoic nodule, about 7.5 cm × 7.1 cm × 6.5 cm in size. However, the nature of the nodule needs to be examined. An auxiliary examination using computed tomography (CT) showed irregular soft tissue masses in the mid-abdomen of the subject

Received: June 26, 2019
Accepted: September 19, 2019
Published Online: September 30, 2019

***CORRESPONDING AUTHOR**
Yi-gang Zuo,
Email: aq3826363@163.com

CITATION
Xue R, Wang H, Li N, Huang Y, Zuo Y. (2019). Primary small cell neuroendocrine carcinoma of the kidney: A case report. *Cancer+*, 1(3):1–4.
DOI: [10.18063/cp.v1i3.241](https://doi.org/10.18063/cp.v1i3.241)

Copyright: © 2019 Xue, *et al.*
This is an Open Access article distributed under the terms of the Creative Commons Attribution-NonCommercial 4.0 International License (<http://creativecommons.org/licenses/by-nc/4.0/>), permitting all non-commercial use, distribution, and reproduction in any medium, provided the original work is properly cited.

which can be seen in the left lower pole of the kidney. These irregular masses are 6.9 cm × 6.1 cm × 5.3 cm in size, adjacent to the region of destroyed renal parenchyma, having unclear boundary, uneven density, and average CT value of 41 Hu [Figure 1]. Enhanced CT scan showed uneven enhancement of some tissues with an average CT value of 75 Hu [Figure 2]. Chest CT showed that the lingual segment of the middle and upper lobes of the right lung was patchy and inflammatory changes were suspected.

2.2 Diagnosis and treatment

Our pre-operative diagnosis of the patient is that the left kidney space was blocked and occupied with malignant tumors that are waiting to be drained. Laparoscopic radical nephrectomy was performed after adequate pre-operative preparation. During the operation, the left subrenal mass was about 7.1 cm × 6.2 cm × 5.0 cm in size, with toughness, unclear boundary, and adhesion to the surrounding tissues. No enlarged lymph nodes were found in the abdominal cavity or retroperitoneum. After the operation, the general

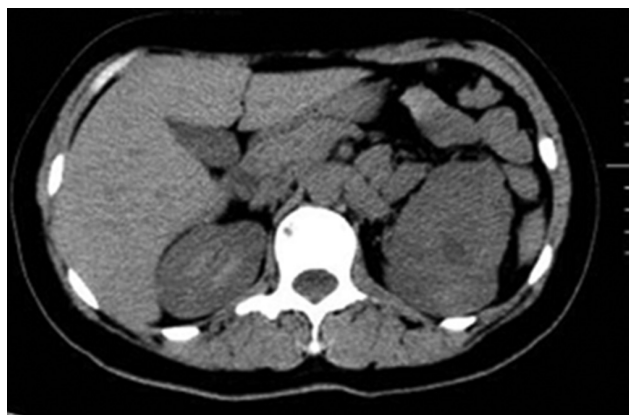

Figure 1. Computed tomography (CT) plain scan of the subject's mid-abdomen. The irregular soft tissue masses can be seen in the left lower pole of the kidney, with a size of 6.9 cm × 6.1 cm × 5.3 cm. These irregular masses are adjacent to the regions of destroyed renal parenchyma, having unclear boundary, uneven density, and an average CT value of 41 Hu.

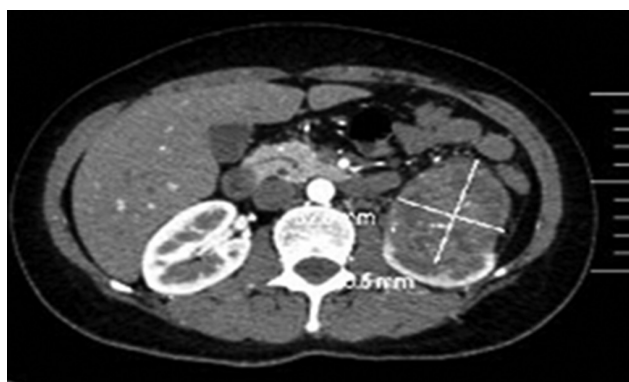


Figure 2. Enhanced computed tomography (CT) scan showing uneven enhancement of some tissues, with an average CT value of 75 Hu.

specimens were gray-white, tough, about 6.8 cm × 5.9 cm × 5.0 cm in size. The specimens had no obvious envelope on the surface, but the incision tissue, gray-white cut surface, and necrosis could be found in the local area.

Based on the pathology report after the surgery, the tumor cells appeared small in size and diffuse in distribution. The cells, with reduced cytoplasm, were arranged in sheets, and the cells were obviously undergoing mitosis. In view of this, the type of the tumor was considered to be small cell neuroendocrine tumor of the kidney [Figure 3]. Immunohistochemistry results of the tumor cells include Ki-67 (40%), CAIX (+), RCC (-), PAX-8 (-), TFE3 (-), SYN (+), NSE (+), SGA (-), CD56 (-), and CD99 (+). Tissue-specific silver staining was also performed, revealing positive result. The images showing the Ki-67 and CAIX immunohistochemical staining are shown in Figure 4A and B, respectively.

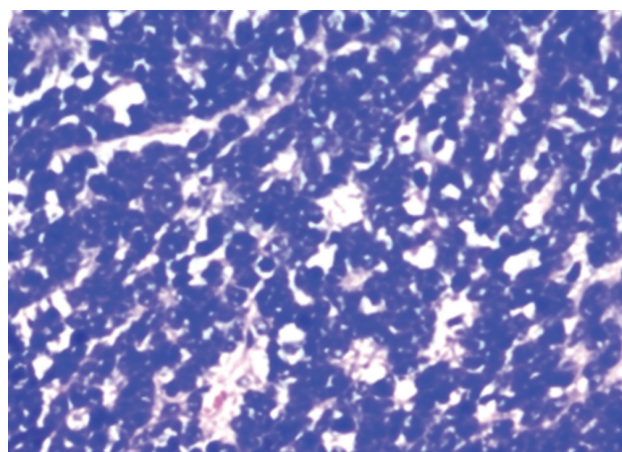


Figure 3. Pathological microscopy showing H and E-stained tumor cells at ×400. The tumor cells appeared small in size and diffuse in distribution. The cells, with reduced cytoplasm, were arranged in sheets and obviously undergoing mitosis. The tumor can be classified as the small cell neuroendocrine carcinoma of kidney.

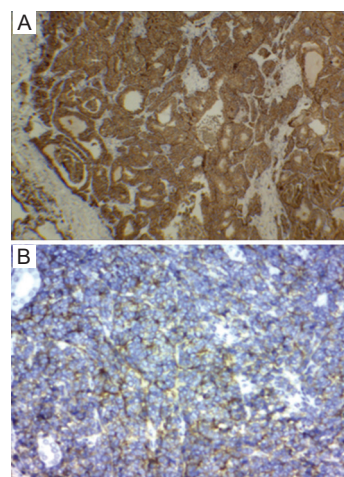


Figure 4. Immunostaining of tumor cells. (A) Ki-67 immunohistochemical staining with a result of 40% of positive staining. (B) Positive CAIX immunostaining.

One month after the surgery, the subject received chemotherapy regimen consisting of etoposide and cisplatin (EP) for only 4 times, without any other treatment. Three months after surgery, CT showed that multiple nodules of different sizes were found in both lungs, and metastasis was considered. Mediastinal lymph node enlargement and retroperitoneal lymph node enlargement were also observed. Systemic bone imaging suggested active bone metabolism in many parts of the body, indicating the possibility of metastatic bone tumors. The subject died of multiple systemic metastases in 7 months after the surgery.

3 Discussion

SCNECs are the most common in the lung, while extrapulmonary carcinomas mainly occur in the gastrointestinal tract and urinary system^[1]. Small cell neuroendocrine carcinomas (SCNECs) in the urinary system predominate in the bladder and prostate^[2]. Nevertheless, SCNEC originating in the kidney is extremely rare. Several reports showed that the incidence of small cell renal cell carcinoma increased significantly in patients with long-term use of immunosuppressive agents^[3]. Small cell renal carcinoma was first reported by Capell. Due to the low incidence of small cell renal cancer, our knowledge and understanding of the small cell carcinoma of the kidney are limited to case reports. SCNEC originates from the cancer stem cells with multidirectional differentiation potential^[4]. SCNEC has a high degree of malignancy, and its clinical manifestations are similar to those of other renal tumors. Most patients with SCNECs originating from other sites may suffer from the ectopic hormone secretion syndrome, while those with renal SCNECs are seldom affected by this syndrome^[5]. The symptoms of ectopic hormone secretion syndrome also disappear or decrease with the removal of the tumor^[6]. Local vascular infiltration, lymph node metastasis, and even distant metastasis have already happened at the time when most patients were in the medical consultation stage^[7]. Although no intravascular tumor thrombus and lymph node enlargement were found in this case, micrometastasis could not be excluded.

SCNEC usually presents as a large solid mass with round or irregular shape and unclear boundary on CT scan. When necrosis occurs in the center, it can be homogeneous and isodense. At the same time, it is accompanied by invasion of adjacent tissues, cancer thrombus in blood vessels, enlargement of lymph nodes, and metastasis in distant areas. On the contrast-enhanced CT scan, slight or irregular enhancement can be seen. Imaging examination is of certain significance for clinical staging, but the final diagnosis still depends on the pathological examination. Under light microscopy, the tumor cells of SCNEC were small, round or short diamond, and arranged in a lamellar nest. Fewer cytoplasm and obvious nuclear mitosis can be observed^[8]. Neuroendocrine markers were presented positive in the immunohistochemical staining of renal small

cell carcinoma. The positive staining of SYN, NSE, CgA, CD56, and CD99 form an important basis for the diagnosis of SCNEC^[7]. SYN is a more sensitive indicator. The positive expression profile of two or more neuroendocrine markers is helpful in the diagnosis and differential diagnosis of small cell carcinoma of the kidney. However, when neuroendocrine markers were negative, renal small cell carcinoma could not be excluded^[9]. The positive expression of SYN, NSE, and CD99 is an important index in the diagnosis of renal small cell carcinoma. Recent studies have found that KI-67 can not only be used as an important indicator for the diagnosis of SCNEC but also be used to judge the malignant degree and prognosis of tumors^[10].

SCNEC is highly malignancy and associated with poor therapeutic effect. At present, there is no uniform, standard treatment for this type of tumor. Radical nephrectomy is a traditional treatment, but whether post-operative chemotherapy or radiotherapy can benefit the patients' survival remains to be studied. Some reports show that SCNEC is more sensitive to chemotherapy than radiotherapy^[11]. Post-operative platinum-based chemotherapy regimen can achieve an average survival time of 17.3 months among patients^[12]. In this case, platinum-based chemotherapy was still used after the surgery, but the survival time of patients did not prolong. This may be related to the presence of multiple systemic micrometastases before the surgery. Therefore, whether post-operative chemotherapy can prolong the survival time of patients is closely related to whether the tumor has distant metastasis. However, it has recently been reported that the use of sunitinib as targeted therapy can benefit follow-up^[13]. Although SCNEC is highly malignant, *in situ* SCNEC confined to the kidney only undergoes radical nephrectomy, and the operative effect is still good and the survival time is as long as 137 months^[8]. Therefore, early diagnosis and treatment of SCNEC is the key to improving the survival of patients.

SCNEC is an extremely rare form of tumor which has poor prognosis. Most clinicians have less clinical experience with this tumor type. At present, a large number of related cases are required to provide a stronger basis for clinical diagnosis and treatment of SCNEC.

4 Conclusion

At present, a large number of related cases are required to provide a stronger basis for clinical diagnosis and treatment of SCNEC.

Conflict of interest

The authors declare that they have no conflicts of interest.

Author contributions

Y.H. performed the immunostaining. N.L. collected the data. R.X. wrote the paper. H.W. and Y.Z. reviewed drafts of the paper.

References

1. Berniker AV, Abdulrahman AA, Teytelboym OM, *et al.*, 2015, Extrapulmonary Small Cell Carcinoma: Imaging Features with Radiologic-pathologic Correlation. *Radiographics*, 35(1):152-63. DOI 10.1148/rg.351140050.
2. Kho VKS, Chan PH, 2010, Primary Small Cell Carcinoma of the Upper Uri Nary Tract. *J Chin Med Assoc*, 73:173-6.
3. Wang X, Wang F, Liang Y, *et al.*, 2018, Primary Small Cell Carcinoma After Renal Transplant: A Case Report. *Medicine*, 97(49):e12592. DOI 10.1097/md.00000000000012592.
4. Chang K, Dai B, Kong YY, *et al.*, 2014, Genitourinary Small-cell Carcinoma: 11-year Treatment Experience. *Asian J Androl*, 16(5):705-9.
5. Majhail NS, Elson P, Bukowski RM, 2003, Therapy and Outcome of Small Cell Carcinoma of the Kidney: Report of Two Cases and a Systematic Review of the Literature. *Cancer*, 97(6):1436-41. DOI 10.1002/cncr.11199.
6. Bahadir HH, Şenol T, Ertoy BD, *et al.*, 2017, Acute Renal Failure Due to Small Cell Neuroendocrine Carcinoma of the Left Kidney: A Case Report. *Oncol Lett*, 14(5):6117-20.
7. Kuroda N, Imamura Y, Hamashima T, *et al.*, 2014, Review of Small Cell Carcinoma of the Kidney with Focus on Clinical and Pathobiological Aspects. *Pol J Pathol*, 65(1):15-9.
8. Si Q, Dancer J, Stanton ML, *et al.*, 2011, Small Cell Carcinoma of the Kidney: A Clinicopathologic Study of 14 Cases. *Hum Pathol*, 42(11):1792-8.
9. Kei-Ichiro U, Nakagawa GO, Katsuaki C, *et al.*, 2013, A Useful Treatment for Patients with Advanced Mixed-type Small Cell Neuroendocrine Carcinoma of the Prostate: A Case Report. *Oncol Lett*, 5(3):793-6.
10. Smits AJ, Vink A, Tolenaars G, *et al.*, 2015, Different Cutoff Values for Thyroid Transcription Factor-1 Antibodies in the Diagnosis of Lung Adenocarcinoma. *Appl Immunohistochem Mol Morphol*, 23(6):416-21. DOI 10.1097/pai.0000000000000099.
11. Jackman DM, Johnson BE, 2005. Small-cell Lung Cancer. *Lancet*, 366(9494):1385-96.
12. Teegavarapu PS, Rao P, Matrana M, *et al.*, 2014, Neuroendocrine Tumors of the Kidney: a Single Institution Experience. *Clin Genitourin Cancer*, 12(6):422-7. DOI 10.1016/j.clgc.2014.06.008.
13. Wang X, Shen H, Yang P, *et al.*, 2017, A Case Report of Sunitinib in the Treatment of Advanced Renal Small Cell Carcinoma. *Chin J Urol*, 38(2):151-2.