

## CASE REPORT

# Transoral Robotic Surgery for Oropharyngeal Cancer

**Arturo Madrid\*, Felipe Capdeville, Luis Felipe Zanolli, Marcelo Orvieto, Hugo Rojas, Felipe Panussis, Fabio Valdés**

Departamento de Cirugía y Oncología Clínica Alemana, Santiago, Republic of Chile

**Abstract:** Oropharyngeal cancer is the main cause of morbidity and mortality of head and neck diseases. For a long time, this traditional treatment is mainly organ protection with radiotherapy and chemotherapy. The undesired effects of medical and surgical treatments have forced people to develop new technologies to manage these diseases. Therefore, since 2006, robotic transoral surgery (TORS) technology has been developing all over the world. So far, the incidence and tumor results of this operation are encouraging, so it is becoming a treatment option that we must deal with. The first two national level cases of oropharyngeal cancer treated with traditional techniques and long-term recurrence in this institution are reported. Resection of the tumor through the trunk and the results of these processes are described.

**Keywords:** Oropharyngeal cancer, Robotic surgery, Oral surgery

**Received:** April 22, 2021  
**Accepted:** June 1, 2021  
**Published Online:** June 14, 2021

**\*CORRESPONDING AUTHOR**  
Arturo Madrid  
E-mail: amadrid@alemana.cl

## CITATION

Madrid A, Capdeville F, Zanolli LF, *et al.*, 2021, Transoral Robotic Surgery for Oropharyngeal Cancer. *Cancer Plus*, 3(2):46–48. DOI: [10.18063/cp.v3i2.366](https://doi.org/10.18063/cp.v3i2.366)

**Copyright:** © 2021, Madrid *et al.*  
This is an Open Access article distributed under the terms of the Creative Commons Attribution-NonCommercial 4.0 International License (<http://creativecommons.org/licenses/by-nc/4.0/>), permitting all noncommercial use, distribution, and reproduction in any medium, provided the original work is properly cited.

## 1. Introduction

Globally, oropharyngeal cancer accounts for 3% of all cancers, with a mortality rate of 8.3 per 100,000 residents<sup>[1]</sup>. In Chile, the incidence rate is 3.3 per 100,000 inhabitants for men and 1.3 for women. According to the estimated data of the ministry of health, the mortality rates for men and women are 1.9 and 0.6 per 100,000 inhabitants, respectively<sup>[2]</sup>. The most common histological change is spinous cell carcinoma, accounting for 95% of cases<sup>[1]</sup>. Smoking, alcohol consumption and human papillomavirus (HPV) infection are the most important pathogenic factors in our environment, especially high-risk serotypes, such as type 16 and 18<sup>[3,4]</sup>. Traditionally, these tumors have been treated by radiotherapy alone, combined therapy (such as radiotherapy plus and/or surgical resection), which has become the least common indication due to its significant associated morbidity. For some time in the past, minimally invasive surgery has been considered as an effective option for the treatment of these tumors, thereby reducing the unnecessary side effects of standard therapy<sup>[5,6]</sup>. In this context, laser oral surgery and robotic oral surgery (tors) have made great progress in the treatment of this tumor pathology in recent years.

TORS was first introduced into literature by Weinstein in 2006<sup>[7]</sup>. Since the publication of this study, the application of tors in the treatment of head and neck malignancies, especially laryngeal and oropharyngeal malignancies, has been developing. It has comparable oncological and functional results, low airway involvement (tracheostomy is not possible) and low swallowing disorders<sup>[5-8]</sup>.

We report two clinical cases of oropharyngeal cancer treated by tors in the head and neck team of our hospital after informed consent.

## 2. Case reports

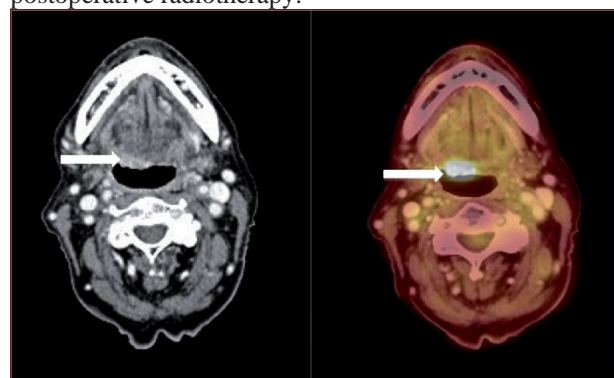
### 2.1. Clinical case 1

We describe a female patient with a history of chronic smoking, 25 packs per year. In 2008, the 78-year-old patient was diagnosed with dysphagia of tongue cancer. The study shows ct1n0m0 standardization and it was evaluated in the head and neck committee. It is recommended to receive radiotherapy only. The patient was treated with oropharyngeal 66 Gy, bilateral cervical lymph nodes 50 Gy. Its development is well tolerated, with mild dysphagia, radial dermatitis with dry mouth and mild dysphagia. It remained under control until October 2013, when an ulcer of about 5 to 8 mm was found at the root of the right tongue during nasal fibrolaryngoscopy. PET-CT (**Figure 1**) showed that the primary tumor site may recur without distant metastasis. Biopsy confirmed acanthocytic carcinoma and was evaluated at the head and neck committee. Considering that he is 82 years old, has an irradiated territory and has a small injury, it is recommended that tors avoid the incidence of open rescue surgery. This work was completed in December 2013. In the existing tracheostomy, an automatic open ring is used to protect the airway. Realization of da vinci® robot 7 (intuitive surgery, sunnyvale, california, USA). After installing the robot arm, complete field of vision of the tumor was checked. In addition to the unipolar pliers and scissors on the robot arm, 0° and 30° optical elements were used (**Figure 2**). Rapid biopsy confirmed free edge tumor resection. The operation was smooth without major bleeding. The patient was sent to the intensive care unit the next day out of mechanical ventilation. Normal swallowing and extubation stoma were performed on the 4th and 5th day after operation. Swallowing was normal on the fourth day after operation. Delayed biopsy confirmed that the edge of spinous process cell carcinoma was negative, so the committee recommended only observation.

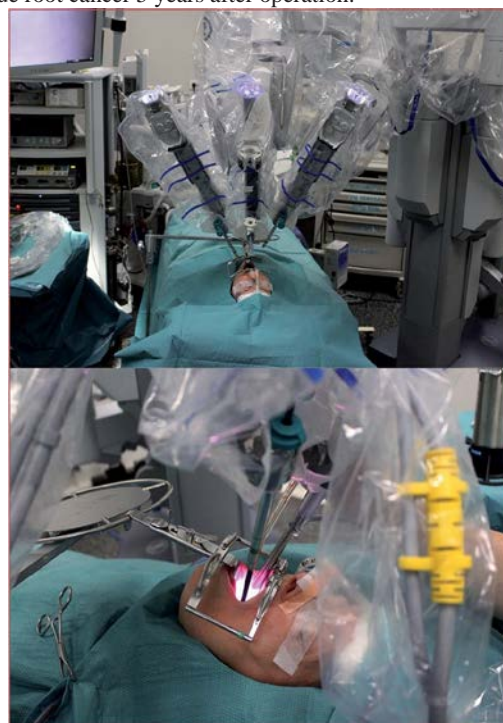
### 2.2. Clinical case 2

A 57-year-old male patient had a history of insulin resistance, alcoholism and smoking for 20 years (30 packs/year). He had a history of soft palate and uvula cancer and received radiotherapy for both neck and primary sites in 1990. In July 2013, biopsy reported squamous cell carcinoma metastasis due to the increase of submandibular gland volume. In addition to the examination under upper airway anesthesia, he also underwent bilateral suprahyoid emptying. The examination showed ulcerative lesions of the tongue root. Delayed biopsy confirmed the existence of a second primary oropharynx without treatment. PET-CT confirmed tongue cancer in addition to adenosis in IA

and IB groups. These medical histories were asked and evaluated by the head and neck committee, and trunk and cervical resection were recommended. In the ward, after tracheostomy, the Da Vinci® robot realized (Intuitive Surgery, Sunnyvale, California, USA). After the robot arm was installed, the full picture of the tumor was examined, and the free boundary was determined by rapid biopsy for resection. After swallowing practice on the sixth day, it developed well. Tracheotomy ended on day 8. Delayed biopsy reported epidermoid carcinoma with a diameter of 2.1 cm, with free but near margin. The postoperative evaluation committee recommends postoperative radiotherapy.



**Figure 1.** PET CT showed the recurrence area of primary tongue root cancer 5 years after operation.



**Figure 2.** Da vinci® robot positioning (intuitive surgery, sunnyvale, CA, USA) for transoral surgery.

## 3. Discussion

The treatment of oropharyngeal cancer has developed in

the past decade<sup>[9]</sup>. At present, radiotherapy or chemoradiotherapy has become the first choice for open surgery, mainly because traditional surgery has many complications, especially in areas requiring or receiving radiotherapy<sup>[10,11]</sup>.

The most common complications in the treatment of these patients include dry mouth, actinic dermatitis, dysphagia, long-term use of tracheotomy and tracheostomy, radioactive osteonecrosis, mucositis and neutropenia, which greatly reduce the quality of life, especially in young patients. In this sense, tors is a tool that allows good tumor control and good functional results to reduce the adverse effects of current standard treatment; even today, these patients were treated with low-dose postoperative radiochemotherapy<sup>[12-14]</sup>.

Tors allow the retention of larger normal tissues, as well as their flushing and innervation, to achieve optimal healing, and avoid unnecessary damage to healthy tissues adjacent to tumors by reducing the wide access required for successful tumor resection.

In recent years, robotic surgery has developed rapidly in China, especially in the field of urology and gynecology. The development of global head and neck is still under continuous evaluation, which is the theme of recent international conferences. We believe that in very special cases, the instructions of this procedure must be very clear and evaluated in advance by a multidisciplinary committee. In China, robotic surgery is pioneering in the treatment of this disease. Over time, we hope to have more experience in the advanced pathological management of these new tools, which will enable us to reduce the risk of traditional treatment for these patients.

## Conflict of interest

The authors declare no conflict of interest.

## References

1. Guzmán P, 2011, Epidermoid Carcinoma of Oral Cavity and Oropharynx. Clinopathological Study. *Reverend Chil Cir*, 63:250–256
2. Ministry of Health of Chile, 2012, Chile's First Cancer Population Record Report. Five Years Period 2003–2007.
3. Dowthwaite SA, Franklin JH, Palma DA, *et al.*, 2012, The Role of Transoral Robotic Surgery in the Management of Oropharyngeal Cancer: A Review of the Literature. *Isrn Oncol*, 2012:945162.
4. Moore EJ, Olsen SM, Laborde RR, *et al.*, 2012, Long-Term Function and Tumor Outcome of Oral Squamous Cell Carcinoma by Oral Robotic Surgery. *Mayo Clinic*, 87:219–225.
5. Nichols AC, Yoo J, Hammond JA, *et al.*, 2013, Early-Stage Squamous Cell Carcinoma of the Oropharynx: Radiotherapy vs Trans-Oral Robotic Surgery (Orator)-Study Protocol for a Randomized Phase II Trial. *BMC Cancer*, 13:133.
6. Rinaldi V, Pagani D, Torretta S, *et al.*, 2013, Transoral Robotic Surgery in the Management of Head and Neck Tumours. *Ecancermedicalscience*, 7:359.
7. Genden EM, O'Malley BW, Weinstein GS, *et al.*, 2012, Transoral Robotic Surgery: Role in the Management of Upper Aerodigestive Tract Tumors. *Head Neck*, 34:886–893.
8. O'Malley BW, Weinstein GS, Snyder W, *et al.*, 2006, Transoral Robotic Surgery (TORS) for Base of Tongue neoplasms. *The Laryngoscope*, 116:1465–1472.
9. Glenny AM, Furness S, Worthington HV, *et al.*, 2010, The CSROC Expert Panel. Interventions for the Treatment of Oral Cavity and Oropharyngeal Cancer: Radiotherapy. *Cochrane Database of Systematic Reviews*, 12:CD006387. DOI: 10.1002/14651858.CD006387.pub2.
10. Langendijk JA, Doornaert P, Verdonck-de Leeuw IM, *et al.*, 2008, Impact of Late Treatment-Related Toxicity on Quality of Life among Patients with Head and Neck Cancer Treated with Radiotherapy. *Journal of Clinical Oncology*, 26:3770–3776.
11. Benson E, Li R, Eisele D, *et al.*, 2014, The Clinical Impact of HPV Tumor Status Upon Head and Neck Squamous Cell Carcinomas. *Oral Oncology*, 50:565–574.
12. Nichols AC, Fung K, Chapeskie C, *et al.*, 2013, Development of a Transoral Robotic Surgery Program in Canada. *J Otolaryngol Head Neck Surg*, 42:8. DOI: 10.1186/1916-0216-42-8.
13. Shah JP, Gil Z, 2009, Current Concepts in Management of Oral Cancer-Surgery. *Oral Oncology*, 45:394–401.DOI: 10.1016/j.oraloncology.2008.05.017.
14. Quon H, Richmon JD, 2012, Treatment Deintensification Strategies for HPV-Associated Head and Neck Carcinomas. *Otolaryngologic Clinics of North America*, 45:845–861.
15. Castillo OA, Vidal I, 2012, Robotic Surgery. *Reverend Chil Cir*, 64:88–91. DOI: 10.4067/s0718-40262012000100016.