

## CASE REPORT

# Leiomyosarcoma of the Bladder: A Case Report

Zhiyong Tan, Li Ning, Jiansong Wang, Yinglong Huang, Haifeng Wang\*, Yigang Zuo\*

Department of Urology, The Second Affiliated Hospital of Kunming Medical University, Yunnan Institute of Urology, Kunming, Yunnan Province, China

**Abstract:** Leiomyosarcomas (LMSs), malignant soft tissue tumor deriving from the mesoderm, account for <0.1% of all bladder malignancies. Conventionally, radical cystectomy with lymph node dissection has been advocated, though some series report that partial cystectomy is acceptable if a negative surgical margin is achieved. Here, we describe a 20-year-old young female presenting with LMS bladder. Computed tomography (CT) and magnetic resonance imaging (MRI) showed a lobulated mass of 2.5 X 3.0 cm on the left lateral side of the bladder. The rest of the bladder appeared normal, with no gross pelvic lymphadenopathy. She performed with transurethral resection of bladder tumor (TURBT). She was diagnosed as LMS though histopathology and immunohistochemistry. Repeat-TURBT was implemented 30 days after the first surgery. Adjuvant chemotherapy was given (Ifosfamide 120 mg/m<sup>2</sup> and Doxorubicin 20 mg/m<sup>2</sup>), and she has been doing well for 12 months of follow-up.

**Keywords:** Diagnosis and treatment, Leiomyosarcoma, Nonurothelial bladder neoplasms

**Received:** August 3, 2021  
**Accepted:** October 4, 2021  
**Published Online:** October 21, 2021

**\*CORRESPONDING AUTHOR**  
Yigang Zuo  
E-mail: yszy924@sina.com  
Haifeng Wang  
E-mail: highphone@126.com

### CITATION

Tan Z, Ning L, Wang J, *et al.*, 2021, Leiomyosarcoma of the Bladder: A Case Report. *Cancer Plus*, 3(4): 48–50.  
DOI: [10.18063/cp.v3i4.218](https://doi.org/10.18063/cp.v3i4.218)

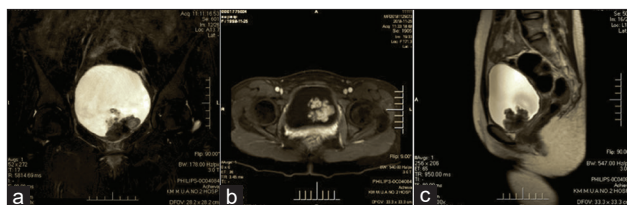**Copyright:** © 2021 Tan *et al.* This is an Open-Access article distributed under the terms of the Creative Commons Attribution-NonCommercial 4.0 International License (<http://creativecommons.org/licenses/by-nc/4.0/>), permitting all non-commercial use, distribution, and reproduction in any medium, provided the original work is properly cited.

## 1. Introduction

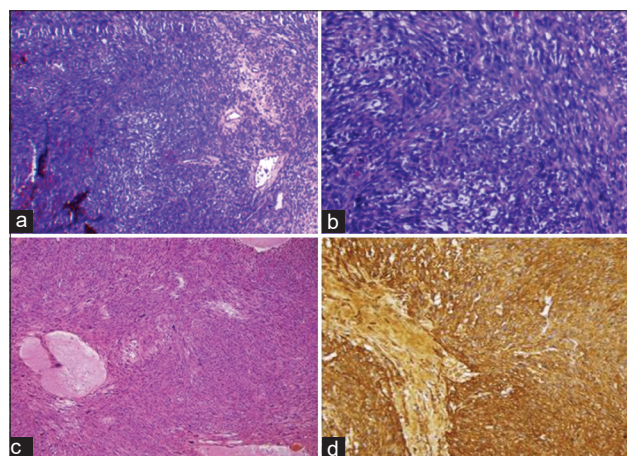
Bladder leiomyosarcoma (LMS) is a rare malignancy. Conventionally, radical cystectomy with lymph node dissection has been advocated. Here, we report a case of bladder LMS managed with TURBT and adjuvant chemotherapy which remains disease free on follow-up of 12 months.

## 2. Case Report

A 20-year-old young female presented with painless gross hematuria for 1 week without fever or bladder irritation. She had never performed radiotherapy or chemotherapy previously. Physical examination was unremarkable. Blood routine: HB 116 g/L, urine routine: Red blood cells 20–50/HP, and white blood cells 40–80/HP. Biochemical and coagulation functions were normal. Tumor markers and 12 items of immunity (including HIV, EB, etc.) were negative. Computed tomography and magnetic resonance imaging (MRI) both showed a lobulated mass of 2.5\*3.0 cm on the left lateral side of the bladder. The rest of the bladder appeared normal, with no gross pelvic lymphadenopathy (Figure 1). Cystoscopic examination showed squamous papilloma of the bladder. Then implemented transurethral resection of bladder tumor (TURBT) and sent the resected tissue for histopathological examination. The tumor was diagnosed as leiomyosarcoma (LMS) by histopathology and immunohistochemistry staining demonstrating the following result (Figure 2). Microscopically, a spindle or ovoid tumor cell with nuclear pleomorphism was arranged densely in a knitted pattern, immunohistochemically, SMA (+), Galdesmon (–), BCL2 (–), Ki67 (25%), Desmin (–), CD34 (+), P53 (+), EMA (–), and S-100 (–). Repeat-TURBT was performed after 30 days. Adjuvant chemotherapy was given (ifosfamide 120 mg/m<sup>2</sup> and Doxorubicin 20 mg/m<sup>2</sup>). During 12 months of MRI and



**Figure 1.** (A-C) magnetic resonance imaging: On the left side of the bladder, there was a 2.5\*3.0 cm irregular and lobulated morphology mass, it appears as slightly longer T1, T2 signal, uneven and limited dispersion, decreasing slightly in delayed enhancement. No gross pelvic lymphadenopathy was detected.



**Figure 2.** (A-D) microscopically, a spindle or ovoid tumor cell with nuclear pleomorphism was arranged densely in a knitted pattern, mitosis is  $<5$  /HP. (HE $\times 400$ ) immunohistochemically, SMA (+), Galdesmon (-), BCL2 (-), Ki67 (25%), Desmin (-), CD34 (+), P53 (+), EMA (-), and S-100 (-).

cystoscopy examination, we did not find any new tumor in her bladder.

### 3. Discussion

LMSs are mesenchymal tumors that tend to occur in organs with abundant smooth muscle, such as the digestive and uterus, while retroperitoneal and bladder LMSs are extremely rare. Fewer than 200 cases have been reported in literature, which accounts for 0.1% of all nonurothelial neoplasms<sup>[1]</sup>. Rowland and Eble reported it first<sup>[2]</sup>. Due to its scarcity, the etiology is rarely learned by people, but there exists strong evidence that patients who received pelvic radiotherapy or systemic chemotherapy such as cyclophosphamide had a higher incidence rate than normal people<sup>[3]</sup>. It has also been reported that patients with retinoblastoma have a significantly increased risk of secondary bladder LMSs, which may be related to the defects of pRb and p16 genes<sup>[4]</sup>. However, the difference with urothelial neoplasms is that bladder LMSs are more likely to occur in the top and side walls, while the trigone of bladder is rare, presenting fungiform, polypoid, and cauliflower. It is usually appear at the age of 50-year-old.

Males were more common, with a ratio of 1.4–1<sup>[5]</sup>.

Gross hematuria, the most common and early symptom, represents over than 80% of cases. Lower urinary tract symptoms are also common, but most of them are late manifestations<sup>[6]</sup>. The tumor is usually first detected on imaging studies and subsequently confirmed on cystoscopy and biopsy. Microscopically, infiltrative interlaced bundles of spindle cells or ovate cells are noted. The nuclei are deeply stained, long rod-shaped, obtuse at both ends, and shaping like “cigar.” Vimentin, muscle-specific actin, and desmin are usually strongly positive on immunohistochemistry. LMS has been subdivided into low- and high-grade based on nuclear atypia, mitotic activity, and tumor necrosis. Low-grade LMS are mild to moderate atypical. Mitosis is  $<5$ /HP. High-grade is highly atypical. Mitosis is  $>5$ /HP<sup>[7]</sup>. In addition, the disease should be differentiated from leiomyoma, rhabdomyosarcoma, and sarcomatoid carcinoma.

Due to its scarcity, there are no established guidelines for management. When its detected, more than 60% of patients are in an advanced stage. At this time, radical cystectomy with free surgical margins is the best choice. It is reported that the 5-year survival rate was 62% and 10-year was 50%. The lungs are the most common site of metastasis, followed by liver and brain<sup>[8]</sup>. However, patients with early-stage, small lesions ( $<4$  cm) and no metastasis. Minimally invasive treatment such as TURBT is an alternative choice<sup>[9]</sup>. Since it can offer a better quality of life, and compared with radical treatment, there is no significant difference in long-term survival rate<sup>[10,11]</sup>. Nevertheless, surgery cannot completely curb the development of tumors, combined with chemotherapy may achieve better results<sup>[12]</sup>. At present, chemotherapy includes AI regimen (isophosphamide and doxorubicin) and IRS-4 regimen (vincristine, cyclophosphamide, actinomycin, and doxorubicin).

There were no swollen lymph nodes observed on preoperative pelvic MRI. The tumor was small ( $<4$  cm) and solitary, did not invade the surrounding tissue. The patient was young and unmarried. Considering the above points, her parents decided to take TURBT. Unfortunately, the tumor was diagnosed as LMS by histopathology. The best out of the worst is that the pathology was low grade and adjuvant chemotherapy was given after operation. Therefore, the patient showed no signs of tumor recurrence and metastasis during 12 months of MRI and cystoscopy follow-up.

Although bladder LMS has usually been considered as a highly invasive neoplasm and has a grim prognosis, one relevant literature reported a 49-year-old female with 4 cm LMS on the bladder neck and anterior wall, performed by TURBT. During 18 months of MRI and cystoscopy follow-up, there were no signs of tumor recurrence and metastasis of her. Therefore, for patients with early stage, small mass ( $<4$  cm), and no metastasis, TURBT is now regarded as a credible method to treat bladder LMS, because it can preserve bladder function and decrease tumor aggressiveness<sup>[13]</sup>.

## 4. Conclusion

Early detection and surgery can essentially enhance the treatment efficacy of bladder LMS. TURBT combined chemotherapy is a reliable method to treat smaller LMS (<4 cm), because it can offer the patient a similar therapeutic efficacy and a better living quality.

## Conflict of interest

Authors declared no conflict of interest.

## References

1. Ribeiro JGA, Klotz CAB, de Araújo CP, 2016, Giant Leiomyosarcoma of the Urinary Bladder. *J Clin Diagn Res*, 10:14–5. DOI: 10.7860/JCDR/2016/18971.7858.
2. Patnayak R, Jena A, Rambabu S, *et al.*, 2015, Leiomyosarcoma of Urinary Bladder-Potential Mimicker of Carcinoma: Case Report and Short Review of Literature. *Indian J Cancer*, 52:573–4. DOI: 10.4103/0019-509X.178433.
3. Slaoui H, Sanchez-Salas R, Validire P, 2014, Urinary Bladder Leiomyosarcoma: Primary Surgical Treatment. *Urol Case Rep*, 2:137–8. DOI: 10.1016/j.eucr.2014.05.002.
4. Liang SX, Lakshmanan Y, Woda BA, *et al.*, 2001, A high-Grade Primary Leiomyosarcoma of the Bladder in a Survivor of Retinoblastoma. *Arch Pathol Lab Med*, 125:1231–4. DOI 10.1043/0003-9985(2001)125<1231:AHGPLO>2.0.CO;2.
5. Zieschang H, Koch R, Manfred PW, *et al.*, 2018, Leiomyosarcoma of the Urinary Bladder in Adult Patients: A Systematic Review of the Literature and Meta-Analysis. *Urol Int* 102:96–101. DOI: 10.1159/000494357. Epub 2018 Nov 1.
6. Wang YH, Hu HL, Zhang Y, *et al.*, 2014, Diagnosis and Treatment of Bladder Leiomyosarcoma (report of 4 cases). *J Mod Urogenital Oncol*, 6:331–3. DOI 10.1016/j.aju.2013.03.004.
7. Lee TK, Miyamoto H, Osunkoya AO, *et al.*, 2010, Smooth Muscle Neoplasms of the Urinary Bladder. A Clinicopathologic Study of 51 Cases. *Am J Surg Pathol*, DOI: 10.1097/PAS.0b013e3181cf326d. 34:502–9.
8. Hamadalla NY, Rifat UN, Safi KC, 2013, Leiomyosarcoma of the Urinary Bladder: A Review and a Report of Two Further Cases. *Arab J Urol*, 11:159–64. DOI: 10.1016/j.aju.2013.03.004.
9. Slaoui H, Barret E, Rozet F, *et al.*, 2014, Urinary Bladder Leiomyosarcoma: Primary Surgical Treatment-Urology Case Reports. *Urol Case Rep*, 2:137–8. DOI: 10.1016/j.eucr.2014.05.002.
10. Ricciardi E, Maniglio P, Schimberni M, *et al.*, 2010, A Case of High-Grade Leiomyosarcoma of the Bladder with Delayed Onset and Very Poor Prognosis. *World J Surgical Oncol*, 8:16. DOI :10.1186/1477-7819-8-16.
11. Gupta DK, Singh V, Sinha RJ, *et al.*, 2013, Leiomyosarcoma, a Nonurothelial Bladder Tumor: A Rare Entity with Therapeutic Diversity. *Korean J Urol*, 54:409. DOI: 10.4111/kju.2013.54.6.409.
12. Xu YF, Wang GC, Zheng JH, *et al.*, 2011, Partial Cystectomy. Is it a Reliable Option for the Treatment of Bladder Leiomyosarcoma? *Can Urol Assoc J*, 5:E11–3. DOI: 10.5489/cuaj.10031.
13. Ryuta S, Dai W, Hirotsushi Y, *et al.*, 2018, Total Endoscopic Management for a Patient with Urinary Bladder Leiomyosarcoma Presenting with Dysuria: A Case Report. *Urol Case Rep*, 20:45–7. DOI: 10.1016/j.eucr.2018.06.012.