

CASE REPORT

Primary Bladder Adenocarcinoma: A Case Report

Yu Huang, Haifeng Wang, Haihao Li, Jingyu Liu, Jiansong Wang*

Department of Urology, The Second Affiliated Hospital of Kunming Medical University, Yunnan Institute of Urology, Kunming 650101, China

Abstract: Primary bladder adenocarcinoma (PBA) is rarely seen in the clinical setting at present. Bladder adenocarcinoma has a special biological behavior, as well as high invasive and metastatic potential. In addition, it is very difficult to diagnose PBA at an early stage. Having similar clinical manifestation to urothelial carcinoma and metastatic adenocarcinoma of the bladder, the differential identification and diagnosis have become more complicated. A majority of adenocarcinoma is not sensitive to radiation and chemotherapy, and thus, the prognosis of PBA is generally poorer. Currently, surgery serves as the principal mode of treatment. In this case report, we had observed a PBA case for 1.5 years, and no recurrence and metastasis had been reported.

Keywords: Bladder tumor, Primary bladder adenocarcinoma, Urachal adenocarcinoma

1. Introduction

Bladder adenocarcinoma is a pathological type of bladder tumor. The incidence rate of primary bladder adenocarcinoma (PBA) is between 0.5% and 2% in all malignant bladder tumors, and higher in those with schistosomiasis infection, villous adenoma, and cystic cyst^[1]. The biological behavior of bladder adenocarcinoma is special, and early diagnosis is difficult. Bladder adenocarcinoma is associated with strong infiltration and metastasis, and high degree of malignancy. Most adenocarcinomas are not sensitive to chemoradiotherapy, and the prognosis is generally poor. Currently, surgical treatment is often used.

2. Case report

The 64-year-old female patient with painless, intermittent gross hematuria for more than half a month was admitted to the hospital. The patient who was also accompanied by frequent and urgent urination, had a history of cerebral infarction 5 years ago. The patient had been taking aspirin, which was discontinued about 2 weeks before the surgery. The patient was born in Yunnan Province, China and had lived in the endemic area for schistosomiasis. The patient also had a medical history of schistosomiasis infection and glandular cystitis.

After admission, relevant examinations were performed. The routine urine test showed that the patient's urine specimen was positive for the presence of erythrocytes but negative for urine protein, whereas 2 – 4 per high power field of urine white blood cells were detected. No abnormal findings were reported from the routine blood test.

Computed tomography (CT) scan which was performed in another hospital showed that the size of the upper wall of the bladder was about 2.2 cm × 1.5 cm. Magnetic resonance imaging (MRI) with an enhancement of the pelvic cavity which was performed in our hospital suggested that a nodular isometric T1, isometric, and slightly longer T2 signal shadow could be seen on the upper wall of the bladder. The boundary was not

Received: January 9, 2022
Accepted: February 10, 2022
Published Online: February 26, 2022

***CORRESPONDING AUTHOR**
Jiansong Wang
E-mail: jiansongwang@126.com

CITATION

Huang Y, Wang H, Li H, *et al.*, 2022, Primary Bladder Adenocarcinoma: A Case Report. *CancerPlus*, 4(1):41–44.
DOI: [10.18063/cp.v4i1.242](https://doi.org/10.18063/cp.v4i1.242)

Copyright: © 2022 Huang *et al.* This is an Open Access article distributed under the terms of the Creative Commons Attribution-NonCommercial 4.0 International License (<http://creativecommons.org/licenses/by-nc/4.0/>), permitting all noncommercial use, distribution, and reproduction in any medium, provided the original work is properly cited.

clear and the size was about 2.4 cm × 1.7 cm × 1.7 cm. Diffusion-weighted imaging signal was high, whereas the apparent diffusion coefficient (ADC) signal was slightly low. The tumor invaded the muscle layer and grew out of the lumen, and the enhancement scan showed an obvious and uneven enhancement. No abnormality was found in the uterus and bilateral appendage, and no enlargement was seen in the pelvic cavity and bilateral inguinal lymph nodes (**Figure 1**). Cystoscopy showed a vegetated mass protruding from the posterior parietal wall of the bladder and invading the submucosal tissue, but no tumor was found elsewhere. The biopsy examination suggested adenocarcinoma of the bladder.

No adhesion was observed between the bladder parietal wall and the surrounding tissues during the surgical operation. The tumor with clear boundaries was located at the junction of the urachus and the bladder parietal wall, and no sign of clear occupation of the tumor was observed in the surrounding intestinal tissue and uterine appendage. Intraoperatively, laparoscopic dilated partial cystectomy was performed, including excision of the entire bladder wall at the bladder tumor coupled with excision of the peritoneum and part of the urachal canal. The incision was soaked with sterile distilled water for about 10 min.

The post-operative pathological examination confirmed that the tumor was moderately differentiated intestinal-type adenocarcinoma. On the other hand, immunohistochemistry results showed that the tumor was positive for cytokeratin 7 (CK7), cytokeratin 20 (CK20) and villin, as well as focally positive for CDX2, but negative for GATA3 (**Figure 2**). According to patient examination, intraoperative conditions and pathological results, this patient was likely to have urachal adenocarcinoma of the bladder.

3. Discussion

According to the histological origin, bladder adenocarcinoma can be divided into three types: primary nonurachal adenocarcinoma, urachal adenocarcinoma, and metastatic adenocarcinoma^[2]. Pathologically, bladder adenocarcinoma can be divided into intestinal, mucinous, signet ring, unspecified adenocarcinoma, and mixed types. Excluding metastatic adenocarcinoma, there are three theories about the origin of bladder adenocarcinoma tissues, including the urachal canal residue theory, the embryonic gland residue theory, and the transitional epithelial gland metaplasia theory of bladder. Among them, glandular metaplasia of bladder epithelium is considered to be the main cause of PBA. Glandular metaplasia of bladder epithelium is mainly due to chronic inflammation of the bladder or the stimulation of stones or carcinogens leading to the proliferation of urothelium to the mucosal lamina propria and the formation of epithelial buds, ensued by the gradual formation of von Brunn's nests, transformation into adenocystitis or cystic cystitis, and finally the development

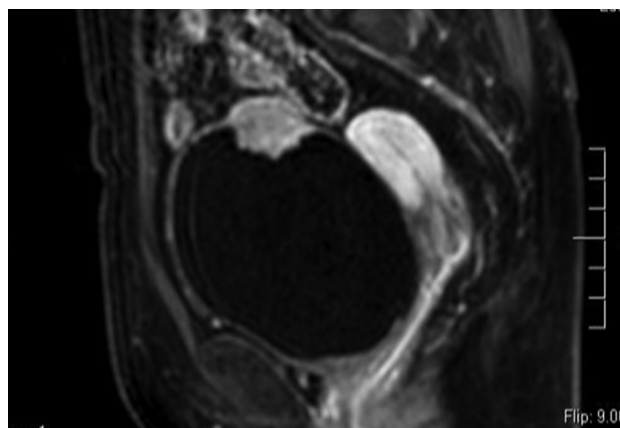


Figure 1. Magnetic resonance imaging of the pelvic cavity with T1-weighted imaging.

of bladder primary adenocarcinoma^[3].

The diagnosis, treatment, and prognosis of secondary adenocarcinoma of the bladder are closely related to the primary lesion. The clinical manifestations of bladder adenocarcinoma are almost the same as those of bladder urothelial carcinoma, and hematuria is the most common clinical manifestation. Some patients may have urinary tract irritation, accompanied by mucus and rotting flesh-like tissues in the urine, and severe urinary retention may occur. For some patients with more severe conditions, the lower abdomen can get in contact with the pubic symphysis, and tumor invasion of peritoneum accompanied by abdominal pain can also be observed. Specific clinical symptoms are related to the location and extent of tumor invasion. The clinical symptoms only started to manifest in most patients with bladder adenocarcinoma in the middle and late stages of diagnosis.

It is highly important to appropriately differentiate the PBA, urothelial carcinoma, and metastatic adenocarcinoma of the bladder. The diagnosis of PBA is the same as that of bladder transitional epithelial carcinoma, but it is difficult to differentiate between them. Currently, ultrasound scan, CT, MRI, and transurethral cystoscopy are mainly used to aid the diagnosis. Compared with urothelial carcinoma, bladder adenocarcinoma mostly presents as a single lesion and is not prone to multicentric and intramucosal recurrence^[4]. Cystoscopy biopsy is the gold standard for diagnosis, which requires multipoint biopsy of tumor tissue to reduce missed diagnosis. Urachal adenocarcinoma and PBA have similar morphology under the microscope and their glands are similarly irregular, most of which are mucinous type and intestinal type, but their immune phenotype is similar. However, urachal adenocarcinoma often occurs in the parietal wall or anterior wall of the bladder which is connected to the abdominal wall tissue, while the PBA often occurs in the trigonum or posterior wall of the bladder and mostly grows along the bladder wall^[5].

PBA must be differentiated from other adenocarcinomas such as prostate adenocarcinoma, intestinal

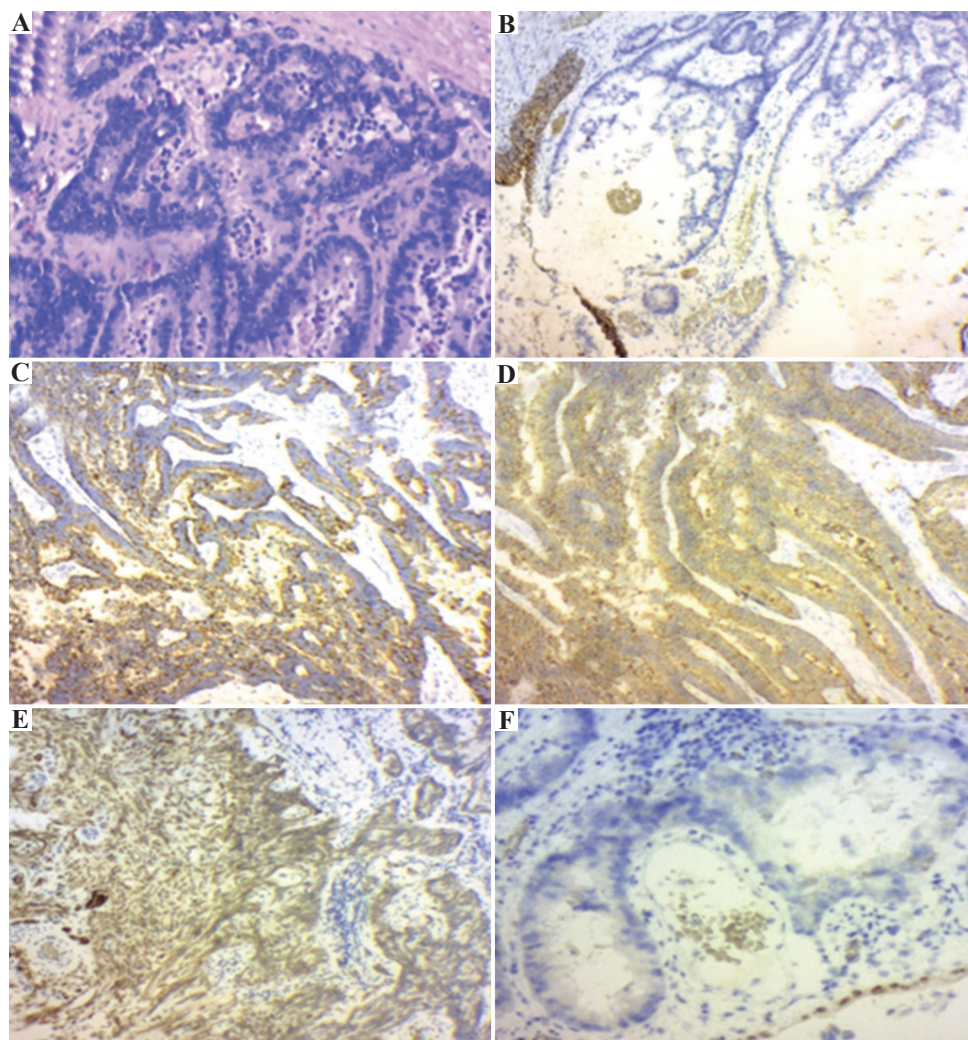


Figure 2. Immunohistochemical staining of the urachus. (A) The urachus was stained with hematoxylin and eosin. The tumor was positive for (B) cytokeratin 7, (C) cytokeratin 20, and (D) villin, as well as focally positive for (E) CDX2, but negative for (F) GATA3.

adenocarcinoma, and endometrial adenocarcinoma that have metastasized to other sites or directly infiltrated into the bladder^[4-7]. For instance, in prostate adenocarcinoma, the tumor cells are arranged in acinar and sieve structure, the nucleoli are enlarged significantly, and the immunohistochemical markers such as prostate-specific antigen and prostatic acid phosphatase are both detected. In addition, the histomorphology of intestinal adenocarcinoma and PBA is very similar, so it is necessary to perform an additional procedure, i.e., immunohistochemistry to accurately differentiate between the two types of adenocarcinomas. Mostly, intestinal adenocarcinoma is tested positive for CK20 and β -catenin, and negative for CK7 and thrombomodulin (TM). On the other hand, PBA is tested positive for CK7, CK20, and TM, and negative for β -catenin. Patients with endometrial adenocarcinoma often experience postmenopausal vaginal bleeding and the immunohistochemistry results reveal the expression of vimentin.

Due to the late onset of symptoms, tumor infiltration, high degree of malignancy, metastasis, and insensitivity to radiotherapy and chemotherapy, bladder adenocarcinoma are often treated by surgery. Bladder adenocarcinoma can easily infiltrate into the muscle layer, and thus, electrosurgical resection of bladder tumors should be considered carefully. Radical cystectomy should be considered for multiple tumors or tumors in the bladder neck, trigone, or bladder base. After the strict screening, partial resection of the enlarged bladder can be performed according to the results of intraoperative frozen section analysis^[5]. Studies have shown that laparoscopic extended partial cystectomy is associated with a higher survival rate in patients with PBA^[6]. Partial cystectomy and radical cystectomy are two main surgical methods. Bruins *et al.* found that there was no significant difference in survival rate in patients who underwent partial bladder resection with radical resection^[8] whether or not to use chemoradiotherapy is still a controversial therapeutic topic. Willian *et al.* stated

that the efficacy of adjuvant or neoadjuvant chemotherapy for urachal adenocarcinoma has not been determined, and most data were derived from case reports that described different chemotherapy regimens and low number of cases, which did not provide statistical significance^[9]. The effect of chemotherapy on PBA needs to be further studied using a large sample in a multicenter clinical trial.

Detection and diagnosis of PBA are relatively challenging because it is difficult to achieve early diagnosis of PBA, the imaging-based diagnostic approaches lack specificity, and the invasiveness of cystoscopy limits its application in the early stage. In view of this, liquid biopsy seems to be an appropriate tool for early diagnosis in the future due to its non-invasive nature. Despite that, the application of liquid biopsy on patients with PBA still warrants further investigation. Moreover, the diagnosed patients should be fully evaluated according to the perioperative situation, and treatment measures should be taken for treatment responsiveness. The patient, in this case, did not receive any chemotherapy or radiotherapy after the surgical operation. The patient has been observed for 1 ½ years, and no recurrence or metastasis has been reported.

4. Conclusion

Early detection and personalized treatment of PBA can improve prognosis and potentially avoid recurrence and metastasis.

Conflict of interest

The authors declare that there are no conflicts of interest regarding the publication of this paper.

Author contributions

All authors read and approved the final manuscript.

References

1. Uhlrig A, Behnesb CL, Strauss A, *et al.*, 2018, Primary Bladder Adenocarcinoma: Case Report with Long-Term follow-Up. *Urol Case Rep*, 18:64–6.
2. Na YQ, Ye ZQ, Sun YH, *et al.*, 2014, Guidelines for Diagnosis and Treatment of Diseases in Chinese Urology. Beijing: People's Medical Publishing House, pp.54.
3. Wang MR, Zhou HL, Gao BS, *et al.*, 2016, Report of 2 Cases of Bladder Adenocarcinoma. *Chin J Lab Diagn*, 20:1776–7.
4. Xu HY, Wang DH, 2017, Advances in the Diagnosis and Treatment of Bladder Adenocarcinoma. *Int J Urol Nephrol*, 37:271–3.
5. Shi YX, Xie YH, Luo B, 2018, A Case of Urachus Adenocarcinoma. *J Clin Exp Pathol*, 34:468–9.
6. Quan J, Pan X, Jin L, *et al.*, 2017, Urachal Carcinoma: Report of Two Cases and Review of the Literature. *Mol Clin Oncol*, 6:101–4.
7. Guo XX, Liu YH, Li WT, *et al.*, 2018, Primary Adenocarcinoma of the Bladder: A Case Report and Literature Review. *Asia Pac Tradit Med*, 14:124–5.
8. Bruins HM, Visser O, Ploeg M, *et al.*, 2012, The Clinical Epidemiology of Urachal Carcinoma: Results of a Large, Population Based Study. *J Urol*, 188:1102–7.
9. Willian S, Marta B, Marco F, *et al.*, 2018, Urachal Adenocarcinoma: A Case Report with Key Imaging Findings and Radiologic-Pathologic Correlation. *Case Rep Radiol*, 2018:4935261. DOI: 10.1155/2018/4935261.