

## Case Report

# Neck Metastasis of Glioblastoma: A Rare Case

 Andina Wirathmawati,<sup>1</sup>  Yuyun Yueniwati,<sup>2</sup>  Dessika Rahmawati,<sup>1</sup>  Eko Arisetijono Marhaendraputro,<sup>1</sup>  
 Shahdevi Nandar Kurniawan<sup>1</sup>

<sup>1</sup>Department of Neurology, Brawijaya University Faculty of Medicine, Malang, Indonesia

<sup>2</sup>Department of Radiology, Brawijaya University Faculty of Medicine, Malang, Indonesia

### Abstract

Glioblastoma (GBM) is the most malignant primary intracranial tumor in adults. Metastases outside the central nervous system (CNS) are very rare. There are several factors for extracranial metastases, e.g. age at diagnosis, lifespan, surgical treatment, and chemoradiotherapy. We present a female patient with a glioblastoma single lesion neck metastasis on her left neck, who had tumor excision, radiotherapy, and chemotherapy and survived for four years.

**Keywords:** Glioblastoma, Extracranial, metastasis glioblastoma, Neck metastasis glioblastoma

**Cite This Article:** Wirathmawati A, Yueniwati Y, Rahmawati D, Marhaendraputro E, Kurniawan S. Neck Metastasis of Glioblastoma: A Rare Case. EJMO 2020;4(3):239–245.

Glioblastoma is the most malignant primary intracranial tumor in adults. The prevalence of primary malignant intracranial tumors, to which men are more prone than women is 33-45%.<sup>[1–3]</sup> The global incidence of glioblastoma is rare, only 3.2 per 100.000 population.<sup>[1, 2]</sup>

Metastases other than CNS were rare in GBM, yet may occur at a frequency of 0.2% and spread to the neck sites. The pathophysiology of extracranial metastases was not fully understood. The hypothesis on the occurrence of extracranial metastases of glioblastoma is a direct lymphatic connection by the venous system and direct invasion by the adjacent structure as dura and bone.<sup>[1]</sup>

The treatment outcome is often an unsatisfactory one. The therapeutic advice methods include a radical surgical procedure and are combined with radio-chemotherapy. Mortality is only three months for untreated patients with median survival time.<sup>[3, 4]</sup> Statistically, the combined therapy has significantly improved the overall survival time from 12.1 to 14.6 months, while the 2-year survival rate was el-

evated to 26.5%, whereas it was 10.4% for those being performed radiotherapy alone.<sup>[4]</sup> Racial impacts were revealed to be a further prognostic according to recent research.<sup>[5]</sup> According to the guideline, secondary glioblastoma is more frequent in women over 45 years of age.

We present glioblastoma with neck metastasis as a rare case.

### Case Report

A 37-year-old woman was referred to the hospital one year before her hospitalization with the main complaints of chronic progressive right hemiparesis and was accompanied by left asymmetrical face and dysarthria; and in its clinical development motoric aphasia, a protruding right eye, and blindness in both eyes, and a mass in the left neck also occur. The patient complained of frequent headaches for seven years before her admission. Two years later, a general tonic-clonic type seizure appeared and the patient received a seizure treatment.

**Address for correspondence:** Andina Wirathmawati, MD. Neurology Resident, Brawijaya University Faculty of Medicine, Malang, Indonesia

**Phone:** +62341556928 **E-mail:** andinanizam@student.ub.ac.id

**Submitted Date:** March 28, 2020 **Accepted Date:** June 01, 2020 **Available Online Date:** July 16, 2020

©Copyright 2020 by Eurasian Journal of Medicine and Oncology - Available online at [www.ejmo.org](http://www.ejmo.org)

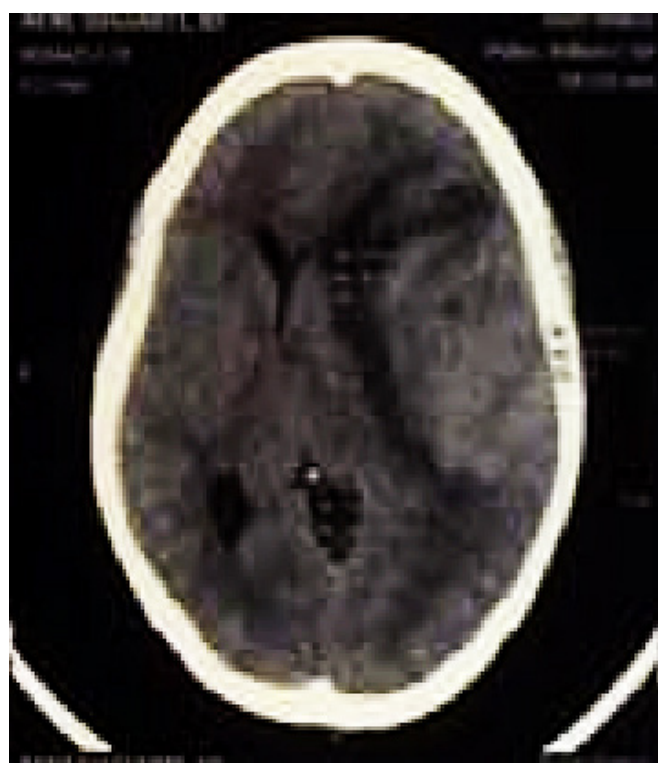
**OPEN ACCESS** This work is licensed under a Creative Commons Attribution-NonCommercial 4.0 International License.



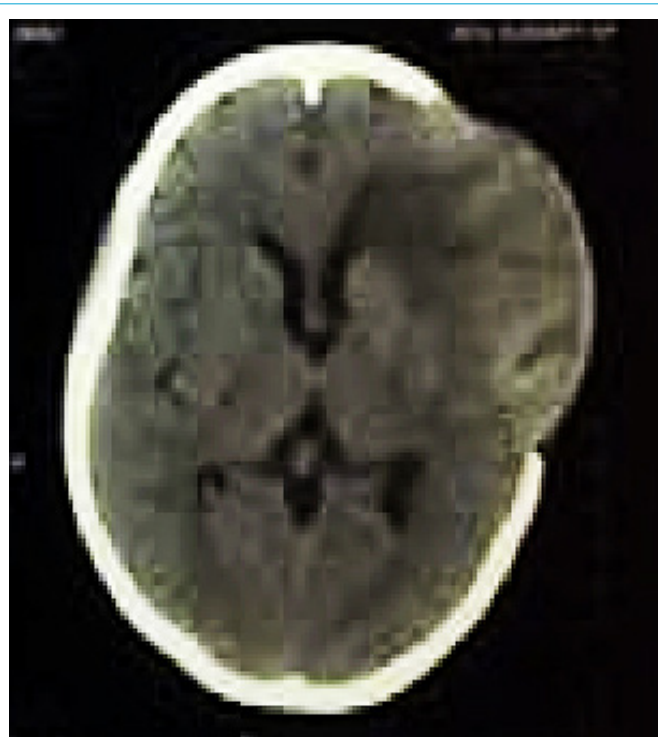
A year later, she presented with blurred vision in both eyes, chronic progressive cephalgia, right half body weakness, right half body numbness, and slurred speech. Computed Tomography (CT) Scan contrast demonstrated it as a brain tumor (Fig. 1). In another hospital, a craniotomy was performed in the left temporoparietal region for a brain tumor in and histopathological examination was carried out revealing Glioblastoma WHO grade IV C71.2, M-94403/3. Post-craniotomy Contrast CT scan was still showing an existing lesion with an enlarged left temporal lobe cortex and decreased lesion size. The post-operative evaluation found extracranial herniation across 26 mm through a 103 mm extensive defect in the left frontotempoparietal os (Fig. 2). After the surgery, the patient recovered smoothly and showed additional symptoms without headache and seizure. Imaging evaluation with MRI (Magnetic Resonance Imaging) was performed one month following the surgery that revealing an increase in tumor size in the left fronto-temporal lobe 35x58x38 cm and in the extracranial herniation to 46 mm. Neuro-oncologic RANO criteria displayed a progressive disease type (Fig. 3).

After one year, she presented with communication problems, disconnected speech, severe headaches and frequently increasing seizures. The patient also complained of pain in her left neck, and there was a newly occurred, single, tender, firm, small 2x2 cm in size palpable mass lesion in the left neck that appears to be suspected lymphadenopathy. The history record revealed that the patient did not routinely check the neurology outpatient clinic a year ago because she was asymptomatic. The head CT scan contrast revealed GBM progression (Fig. 4). We planned the surgical resection of the brain tumor, but it was refused by the patient's family and she received brain radiotherapy (20 Gy).

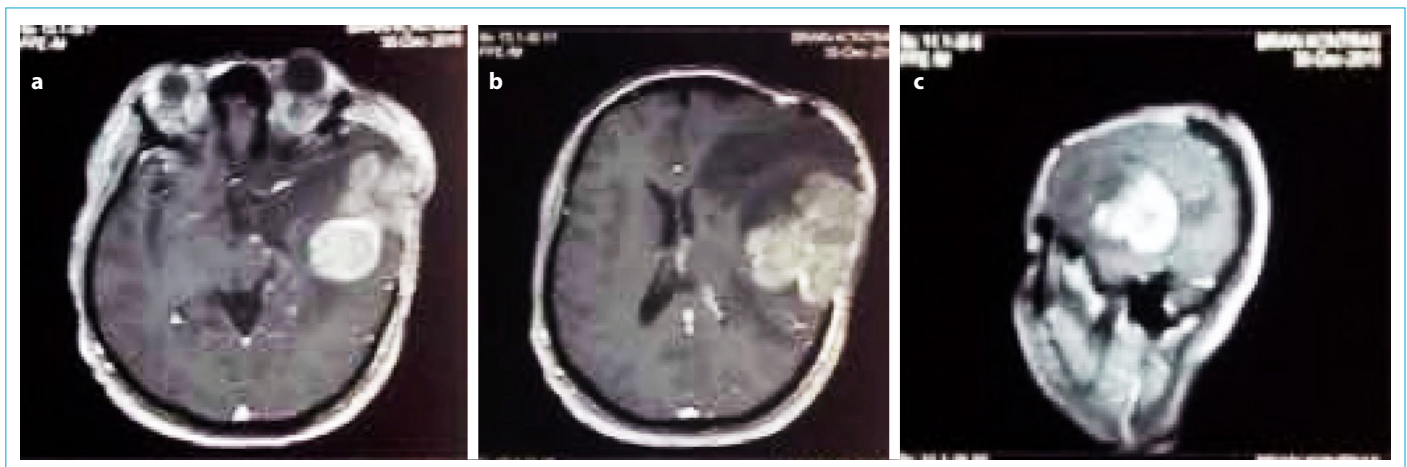
After one year, due to the poor patient compliance, and worsening symptoms like a mass lesion in the left neck that enlarged to 10x8 cm than previous with hyperemia, hard and irregular edges (Fig. 5), the brain tumor resection was approved by the patient's family. The histopathological finding following the surgery showed a consistent recurrence of GBM (WHO grade IV), suggesting IHK with GFAP, CK (Fig. 6). In the evaluation of the head CT scan following the surgery, the left region showed a solid lesion in the occipital and the left region suspected pneumocephalus and left-sided lymphadenopathy in the frontotemporal region (Fig. 7). Combined therapy was chosen in concomitant chemoradiotherapy with a dose of radiotherapy 60 Gy in 30 fractions followed by chemotherapy temozolomide that was given at 75mg/m<sup>2</sup> PO daily for 42 days. Evaluation after concomitant radiochemotherapy with MRI of the brain and neck revealed cystic encephalomalacia with a solid le-



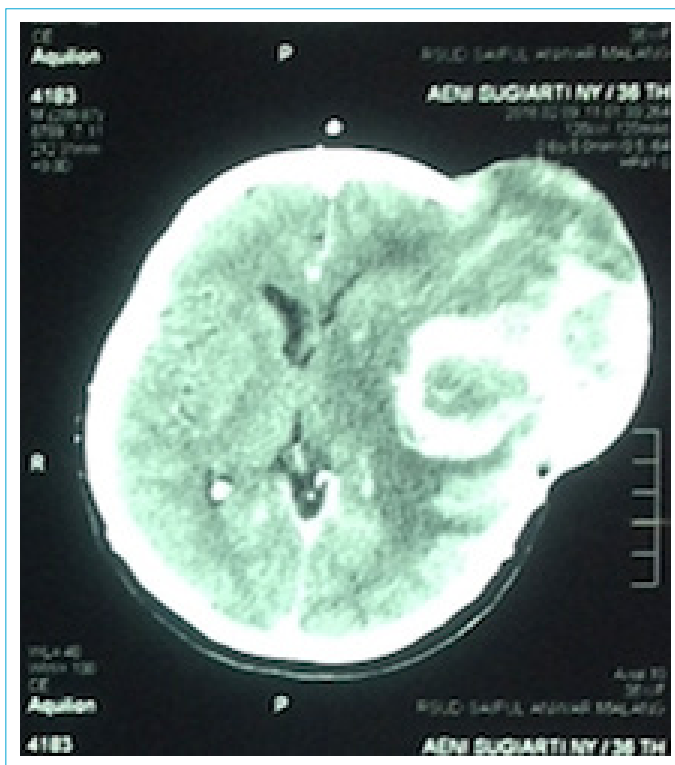
**Figure 1.** Contrast-enhanced computed tomography (CT) scan demonstrated as a brain tumor in the left temporoparietal region.



**Figure 2.** Contrast CT scan post craniotomy showed lesion still present with enhancement in the left temporal lobe cortex, reduced lesion size. Extracranial herniation as far as 26 mm, through a 103 mm extensive defect in the left frontotempoparietal os (postsurgery).

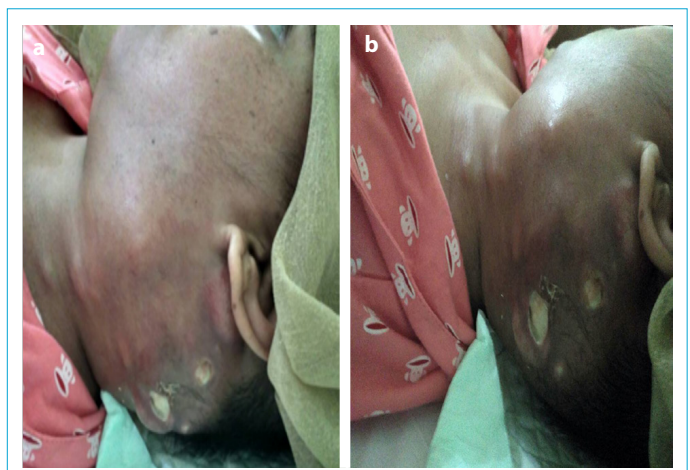

**Figure 3.** Magnetic resonance images (MRI) scans taken one month later revealed; **(a)** hypointense cystic lesions T1W1/FLAIR hyperintense T2W1 partly with solid isointense. T1W1/T2W1 hyperintense FLAIR enhancement partly at the edges and in the post-contrast part of the solid in the left frontotemporal lobe measuring 35x58x38 cm. **(b)** Extracranial herniation as far as 46 mm, through a 103 mm extensive defect on the left frontotempoparietal os (post-surgery), increase lesion size. **(c)** MRI sagittal view showed increased enhancing mass of the left frontotemporal lobe.

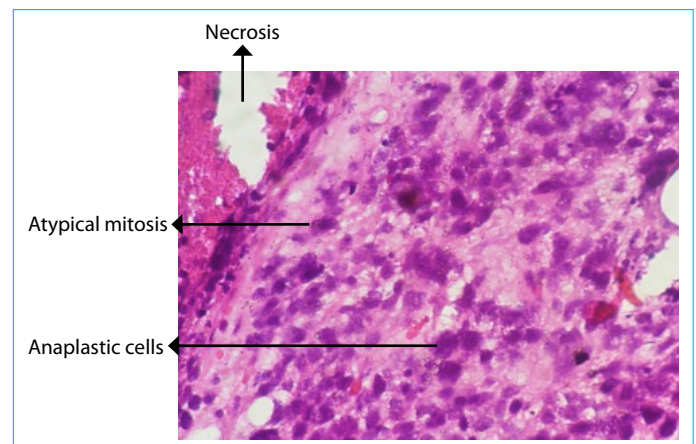


**Figure 4.** Contrast-enhanced Computer tomography (CT) scan image taken after the first surgery noted the GBM progression.

sion in the left frontotemporal lobe, suggesting a residual mass. The mass in the left posterior colli region suggested malignancy (Fig. 8). Fine needle aspiration biopsy on the left neck mass showed small round cell tumors indicating a blastoma, suggestive of ICC LCA (Fig. 9). Immunohistochemistry examination revealed positive glial fibrillary acidic protein (GFAP), and positive neuron-specific enolase (NSE) indicating metastatic GBM (Fig. 10). All pathological

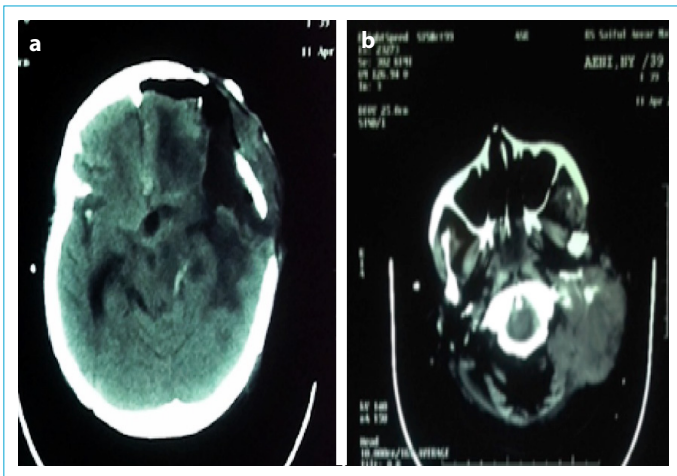


**Figure 5.** **(a)** Lateral view of left neck mass 10x8 cm, hyperemia, hard, and had irregular edges. **(b)** Posterolateral view of left neck mass 10x8 cm, hyperemia, hard, and had irregular edges.

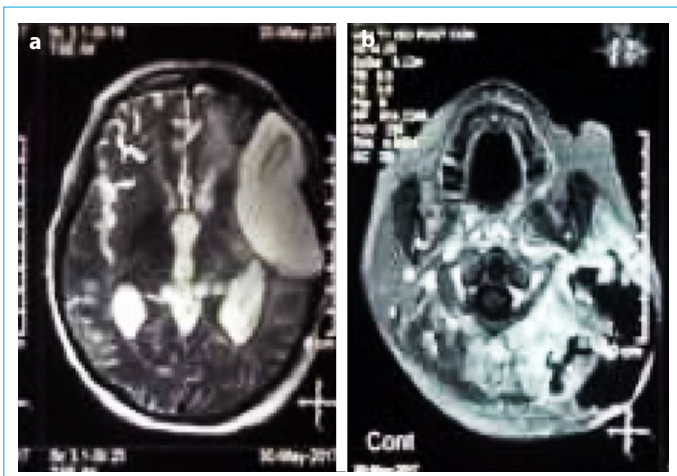


**Figure 6.** The brain tumor histopathological finding was an accordant recurrence of the GBM (WHO grade IV), suggestion IHK with GFAP, CK (hematoxylin-eosin, x400).

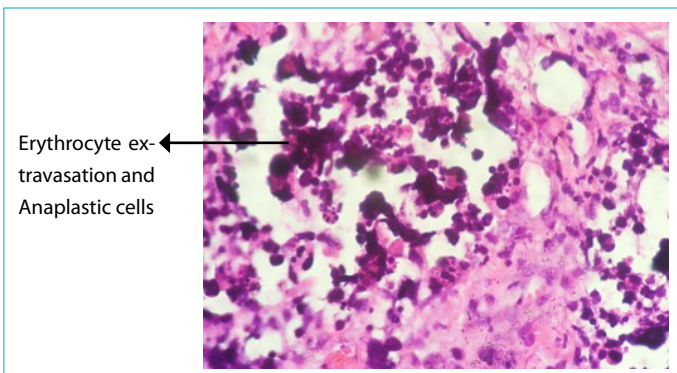




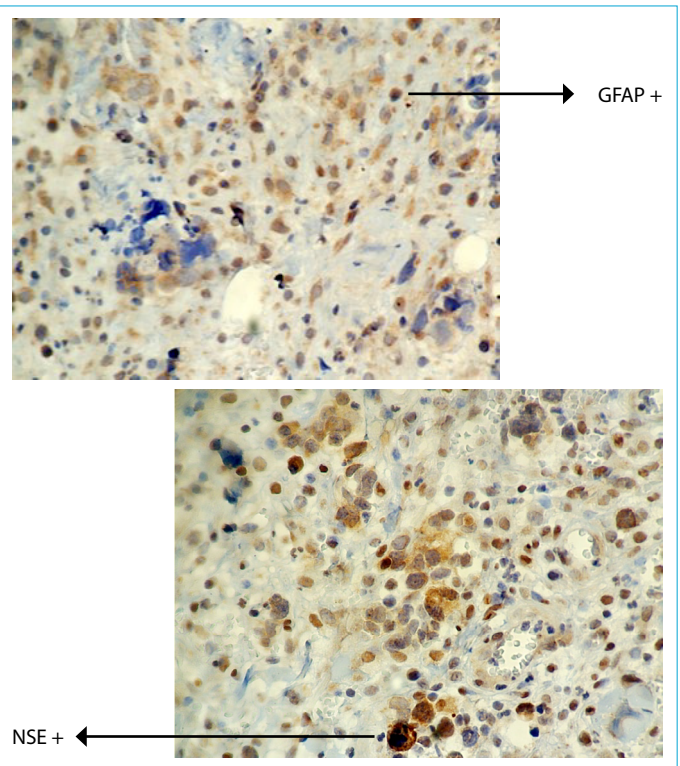
**Figure 7.** (a) Head CT scan evaluation after surgery showed a pneumocephalus in the left regio frontotemporal, (b) solid lesion in the left regio occipital until the left colli suspect lymphadenopathy.



**Figure 8.** The brain and neck MRI after surgery followed concomitant radiochemotherapy revealed; (a) cystic encephalomalacia in the left frontotemporal lobe with a solid lesion in it suggested a residual mass. (b) The mass in the left posterior colli region suggested malignancy.



**Figure 9.** Fine needle aspiration biopsy of neck mass showed small round cell tumor indicated to a blastoma, suggestion ICC LCA (hematoxylin-eosin, x400).



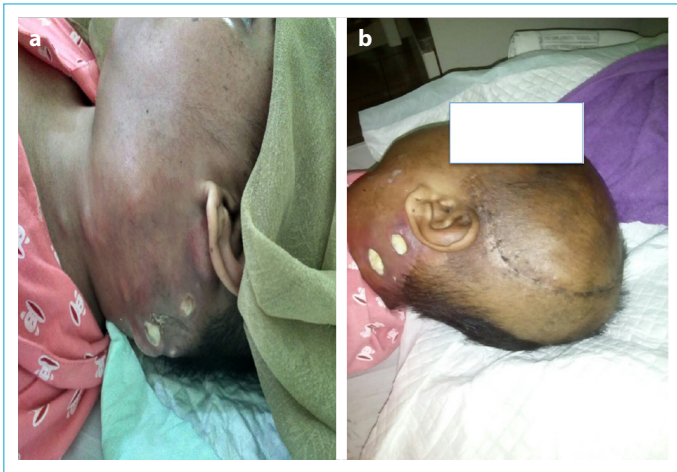**Figure 10.** Immunohistochemistry examination revealed; (a) positive glial fibrillary acidic protein (GFAP), and (b) positive neuron-specific enolase (NSE) indicated metastatic GBM.

samples taken from the brain tumor and the neck mass were confirmed as GBM.

Round discussion between a neurologist, neurosurgeon, oncology surgeon, department of internal medicine hematology/oncology, radiologist, pathology assistant, took a decision for combined therapy with 5x3gy colli radiotherapy, and to continue 150 mg/m<sup>2</sup> oral adjuvant temozolomide on the day 1 and 5 for every 28 days in six cycles. f. The excision of tumor mass in the left neck was planned. Her condition remained stable during adjuvant chemotherapy with temozolomide. She showed an improvement in colli tumor size reduction (Fig. 11) and did not complain of headache and seizures, loss of appetite, and she had 3.5 kg weight gain. The patient was not checked again. After three months, the condition of patient deteriorated and died due to the progression of the GBM.

## Discussion

Epidemiology has shown that the majority of cases (>90%) are the most prevalent primary glioblastomas, which are mostly affects in the elderly with a mean age of 62 years, but may still appear in a lower percentage of cases. Secondary glioblastomas occur in younger patients with a mean age of 45 years. It is more common in women than men



**Figure 11. (a)** Lateral view of left neck mass 10x8 cm, hyperemia, hard, and had irregular edges, before neck radiotherapy **(b)** Decrease the size of the mass left neck after neck radiotherapy.

progresses rapidly from low-grade diffuse astrocytoma (WHO grade II) or anaplastic astrocytoma (WHO grade III).<sup>[23, 24]</sup> For secondary glioblastoma, clinical (neuroimaging) or histopathological (biopsy) diagnostic criteria evidencing progressively malignant astrocytoma are required.

The Hypotheses regarding rare GBM metastases might be explained by the following reasons: It is well known and broadly accepted that physical barriers around the cerebral (dura mater, thickened basement membrane, and BBB/ blood-brain barrier) is a substantial barrier preventing the spread of tumor cells beyond the brain. Since there is no connection in the perivascular spaces extracerebral fluid space make metastasis difficult to spread. However, 20% of GBM patients showed CTC (circulating tumor cells) in peripheral blood even if they did not have metastases. Apparently, CTC is impeded in finding access to adjacent organs. This may be explained by the intrinsic properties of glial filament, or by the fact that the peripheral immune response of the host organ to neuroglial tumor cells, can may prevent extraneural metastasis, extraneural, or by ECM (extracellular matrix proteins) deficiency such as collagen and fibronectin overexpressed in the hyperplastic blood vessels. Through hyaluronic acid and other glycosaminoglycans, the main components of the extracellular spaces, tumor cells can migrate into the tissue. This property of the extracellular substrates can rarely cause hematogenous metastasis.<sup>[1, 27–29]</sup> The other hypotheses are the absence of intracranial lymphatic vessels, and very sparse connections between extracranial lymphatic vessels and the sub-arachnoid space.

There are several factors for GBM neck metastases, the first of which is diagnosis age and metastasis is more prevalent at younger ages. In 1928, Davis was the first to present a

case of metastatic GBM. A recent article revealed about y 200 cases of metastasis in GBM patients. Epidemiology showed that younger and healthier patients are more prone to develop extracranial metastases than elder GBM.<sup>[26–28]</sup> The second factor is the overall survival rate at which life expectancy increases with better diagnostics and treatment. The third factor is surgical treatment; almost 96% of patients with GBM metastases have surgical treatment. Huang et al. explained the extraneural spread following the neurosurgical operation. Tumor cells may access the blood circulation by crossing the damaged blood-brain barrier (BBB) and dura mater. Craniotomy with tumor resection is associated with the opening of the brain vessels and in this respect may be associated with the spread of tumor cells. In the present case, the patient underwent two operations, which might increase the probability of distant metastasis, the direct invasion through the dura and bone, or tumor cell migration along with the ventriculoperitoneal shunts. The fourth factor is the lymphatic cerebrospinal fluid drainage into the extraneural tissue (despite no identifiable lymphatic system in the CNS). The fifth factor is the venous invasion through either the leptomeningeal sinuses or the dural vein; The last factor is chemoradiotherapy, which causes excessive apoptosis and DNA damage in the brain tissue as well as in tumor cells, and this causes inhibition of glioma angiogenesis but this increased tumor cell invasion in the brain tissue.<sup>[27, 28, 30, 31]</sup>

As is known, the Guideline for GBM therapy consists of performing a craniotomy followed by radiation and chemotherapy.<sup>[33]</sup> The primary goal of surgery is to remove as much of the tumor as possible without damaging the surrounding normal brain tissue, which is essential for normal neurological function. After the wound heals, radiotherapy begins to selectively eradicate any remaining tumor cells that have infiltrated the normal brain tissue surrounding the wound. Radiotherapy use has better outcomes and longer survival rates than surgery alone. Chemotherapy is designed to eradicate tumor cells as a combined therapy with radiotherapy. Temozolomide is the current standard treatment for GBM. In our case, surgery and biopsy were performed with good results, but the second-phase therapy with radiotherapy could not be provided because the patient did not routinely attend follow-ups and refused to take further medication. Recent research revealed that surgical treatment alone either with biopsy or brain resection has a survival rate of 0.2 and 0.6 in 3 months, respectively.<sup>[34]</sup>

In the second incident, one year later, it turned out to be recurrent and progressive GBM. The medication was only given by radiotherapy as the patient refused brain resection. Recurrent glioblastoma is an unavoidable possibility of recurrent GBM after a median survival time of 32-36



weeks, especially in cases where patient compliance is inadequate.<sup>[39]</sup> Recurrence in our case was more than 36 weeks progressive symptoms that occurred might due to previous therapy. The best medical option for recurrent GBM was combined therapy with surgery and chemoradiotherapy; recent research revealed that adjuvant treatment and systemic treatment after re-resection had significantly longer survival rates than patients receiving supportive care (7.3 and 11.0 vs. 3.1 months respectively [HR 0.46 ( $p < 0.001$ ) and 0.36 ( $p < 0.001$ )].<sup>[40]</sup>

In the third incidence, recurrent GBM was worsening, and combined therapy was applied. Even if the optimal medicaments were administered, after a round discussion among experts, a new approach was adopted and a good result was obtained. The survival rate for GBM patients is disastrous. Tamimi et al. showed that only a few patients survived 2.5 years and less than 5% of patients survived five years following the treatment.<sup>[35]</sup> Patient survival median time is estimated between 12 and 18 months with maximal therapy, but those without any intervention die immediately after the diagnosis.<sup>36</sup> In a large retrospective study, Scott et al. revealed that 2.2% of the cohort survived for >2 years, but the overall five-year survival rate is only <10% with a mortality rate of almost 100%.<sup>[37, 38]</sup> In our case, the patient had 4-years of survival time and made good progress, yet had poor patient compliance.

This case should be considered as an acceptable GBM extracranial metastases case. According to Weiss, such cases include: (1) the presence of a single histologically characteristic primary brain tumor should be proven; (2) the clinical histories should be originated from this tumor; (3) a complete autopsy should be performed to rule out possibility of any other primary tumor; and (4) the putative extracranial metastases.<sup>[32]</sup>

In this case, the the GBM neck metastatic patient underwent two surgeries and received radiotherapy concomitant with chemotherapy. The patient survived for 2.5 years, which is longer than the survival rate for most GBM patients.

## Conclusion

Neck metastatic glioblastoma of the patient presented the possibility that the leading risk factors were recurrent surgeries, a long lifespan, and chemoradiotherapy.

## Disclosures

**Declaration of patient consent:** The authors certify that they have obtained all appropriate patient consent forms. In the form, patients gave their consent for their images and other clinical information to be reported in the journal. The patients understand that their names and initials will not be published.

**Informed consent:** Written informed consent was obtained from the patient for the publication of the case report and the accompanying images.

**Peer-review:** Externally peer-reviewed.

**Conflict of Interest:** None declared.

**Authorship Contributions:** Concept – A.W.; Design – A.W.; Supervision – Y.Y., D.R., E.A., S.N.; Materials – A.W.; Data collection &/ or processing – A.W., Y.Y., ; Analysis and/or interpretation – D.R., E.A., S.N.; Literature search – A.W., D.R., Y.Y.; Writing – A.W., D.R., Y.Y.; Critical review – Y.Y., D.R., E.A., S.N.

## References

1. Rahmawati D, Marhaendraputro EA, Kurniawan SN, Wirathmawati A. Extracranial metastasis of glioblastoma: a rare case. *Malang Neurology Journal* 2019;5:51–54.
2. Haroon S and Faridi NF. Cervical metastatic glioblastoma multiforme. *Journal of the College of Physicians and Surgeons Pakistan* 2013;23:160–1.
3. Yueniwati Y. *Pencitraan pada Tumor Otak*. Universitas Brawijaya Press 2017.
4. Visser O, Ardanaz E, Botta L, Sant M, Tavilla A, Minicocchi P, Survival of adults with primary malignant brain tumors in Europe; results of the euro care-5 study. *Euro care-5 Working Group: Eur J Cancer* 2015;51:2231–2241.
5. Hoffman HJ, Duffner PK. Extra neural metastasis of central nervous system tumors. *Cancer*; 1985.1;56(7 Suppl):1778-82. PubMed: <https://www.ncbi.nlm.nih.gov/pubmed/4027909>
6. Catherine C, Park, et al. Systemic Metastasis in glioblastoma may represent the emergence of neoplastic subclones. *J Neuropathol Exp Neurol*;2000.59:1044–50.
7. Piccirilli M, Brunetto GM, Rocchi G, Giangaspero F, Salvati M. Extra central nervous system metastasis from cerebral glioblastoma multiforme in elderly patients. *Clinicopathological remarks on our series of seven cases and critical review of the literature*. *Tumor* 2008;94:40–51. PubMed: <https://www.ncbi.nlm.nih.gov/pubmed/18468334>
8. Polley MY, Lamborn KR, Chang SM, Butowski N, Clarke JL, Prados M. Conditional probability of survival in patients with newly diagnosed glioblastoma. *J Clin Oncol* 2011;1:29:4175–80.
9. Anghileri E, Castiglione M, Nunziata R, Boffano C, Nazzi V, Acerbi F, et al. Extra neural metastasis in glioblastoma patients: two cases with ykl-40-positive glioblastomas and a meta-analysis of the literature. *Neurosurg Rev* 2016;39:37–45; discussion 45–6.
10. Huang P, Allam A, Taghian A, Freeman J, Duffy M, Suit HD. Growth and metastatic behavior of five human glioblastomas compared with nine other histological types of human tumor xenografts in scid mice. *J Neurosurg* 1995;83:308–15. PubMed: <https://www.ncbi.nlm.nih.gov/pubmed/7616277>
11. Schweitzer T, Vince GH, Herbold C, Roosen K, Tonn JC. Extraneural metastases of primary brain tumors. *J Neurooncol* 2001;53:107–14. PubMed: <https://www.ncbi.nlm.nih.gov/>

- pubmed/11716064
12. Zustovich F, Della Puppa A, Scienza R, Anselmi P, Furlan C, Car-tei G. Metastatic oligodendrogliomas: a review of the litera-ture and case report. *Acta Neurochir (Wien)*; 2008;150:699–702; discussion 702–3.
  13. Alam ABN, Rahayu M, Islani AZS. Effect of the radiation of gamma rays on caspase-3 expression in *Rattus norvegicus* Wistar male variant brain cell with immunohistochemistry method. *Malang Neurology Journal* 2015;1:72–9.
  14. Tuettenberg J, Grobholz R, Korn T, Wenz F, Erber R, Vajkoczy P. Continuous low-dose chemotherapy plus inhibition of cy-clooxygenase-2 as an antiangiogenic therapy of glioblastoma multiforme. *J Cancer Res Clin Oncol* 2005;131:31–40.
  15. Cervio A, Piedimonte F, Salaberry J, Alcorta SC, Salvat J, Diez B, et al. Bone metastases from secondary glioblastoma multi-forme: a case report. *J Neurooncol* 2001;52:141–8.
  16. Kaye A, Laws Jr E. *Brain tumors*. Philadelphia: Churchill Living-stone; 2001.
  17. Hsu E, Keene D, Ventureyra E, et al. Bone marrow metastasis in astrocytic glioma. *J Neurooncol* 1998;37:285–93. PubMed: <https://www.ncbi.nlm.nih.gov/pubmed/9524086>
  18. Hiroko O and Paul K. Genetic pathways to Primary and Sec-ondary Glioblastoma. *The American Journal of Pathology*; Vol 170 No May 5, 2007.
  19. Butowski N, Chang S. Adult High-Grade Glioma. In: Barret GH. *High-grade Glioma*. New Jersey: Humana Press, 2007: p59-60
  20. Ostrom QT, Gittleman H, Fulop J, Liu M, Blanda R, Kromer C, Barnholtz-Sloan JS. CBTRUS statistical report: Primary brain and central nervous system tumors diagnosed in the United States in 2008–2012. *Neuro-Oncology* 2015;17(Suppl. 4): iv1–v62.
  21. Ostrom QT, Gittleman H, Liao P, Rouse C, Chen Y, Dowling J, Barnholtz-Sloan J. CBTRUS statistical report: Primary brain and central nervous system tumors diagnosed in the United States in 2007–2011. *Neuro-Oncology* 2014;16(Suppl. 4): iv1–63.
  22. Tamimi A.F and Jumeid M. Chapter 8 Epidemiology and out-come glioblastoma in *Glioblastoma Bookshelf*. De Vleeschou-er S, editor Brisbane (AU): Codon Publications; 2017 Sep 27.
  23. Nizamutdinov D, Stock E.M, Dandashi J.A, et.al. Prognostica-tion of survival outcomes in patients diagnosed with glioblas-toma. *World neurosurgery* 109: E67-E74, January 2018.
  24. Yueniwati Y, Wangsadjaja C, Yulidani I, Rianawati SB, Al Rasyid H. The role of Brain Magnetic Resonance Imaging (MRI) as an early detector of cognitive impairment. *J Neurosci Rural Pract* 2018;9:350–3.
  25. Hiroko O and Paul K. Genetic pathways to Primary and Sec-ondary Glioblastoma. *The American Journal of Pathology*; Vol 170 No 5, May 2007.
  26. Kup PG, Nieder C, Winnekendonk G, Adamietz IA, Fakhrian K. Extracranial oral cavity metastasis from glioblastoma multi-forme: A case report. *Mol Clin Oncol* 2016;5:437–9.
  27. Müller C, Holtschmidt J, Auer M, Heitzer E, Lamszus K, Schulte A, et al. Hematogenous dissemination of glioblastoma multi-forme. *Sci Transl Med* 2014;6:247ra101.
  28. Singh G, Mehrotra A, Sardhara J, et.al. Multiple glioblastomas: are different from their solitary counterparts? *Asian J Neuro-surg* 2015;10:266–271.
  29. Ray A, Manjila S, Hdeib AM, Radhakrishnan A, Nock CJ, Cohen ML, et al. Extracranial metastasis of glioblastoma: three illus-trative cases and current review of the molecular pathology and management strategies. *Mol Clin Oncol* 2015;3:479–86.
  30. Rosen J, Blau T, Grau S.J, et.al. Extracranial metastases of a ce-rebral glioblastoma: a case report and review of the literature. *Case Rep Oncol* 2018;11:591–600.
  31. Izci Y, Akay KM, Gurkanlar D, Deveci MS. Radiation-induced glioblastoma multiforme following surgery for medulloblas-toma in a child with neurofibromatosis-1: A Case report. *Turk Neurosurg* 2005;15:71–5.
  32. Weiss L. A metastasizing ependymoma of the cauda equine. *Cancer* 1955;8:161–71.
  33. Glioblastoma Multiforme. Aans.org.
  34. Michael E.Berens and Alg Giese. "...those left behind." *Biology and Oncology of Invasive Glioma Cells*. *NEoplasia* 1999;1:208–19.
  35. Ahmad Faleh Tamimi and Malik Juweid. Chapter 8: epidemiol-ogy and outcome of glioblastoma. *Glioblastoma NCBI Book-shelf*.
  36. McLendon RE and Halperin EC. Is the long-term survival of pa-tients with intracranial glioblastoma multiforme overstated? *Cancer* 2003;98:1745–8.
  37. Scott JN, Rewcastle NB, Brasher PM, et al. Long-term glioblas-toma multiforme survivors: A population-based study. *Can J Neurol Sci* 1998;25:197–201.
  38. Kleihues P, Sobin LH. World Health Organization classification of tumors. *Cancer* 2000;88:2887.
  39. Ammirati M, Galicich JH, Arbit E, Liao Y. Reoperation in the treatment of recurrent intracranial malignant gliomas. *Neu-ro-surgery* 1987;21:607–14.
  40. Myra E. van Linde, Cyrillo G. Brahm, et al. Treatment outcome of patients with recurrent glioblastoma multiforme: a retro-spective multicenter analysis. *J Neurooncol* 2017;135:183–192.