




























## Review

# Multisystemic Long-Term Sequelae of Covid-19: A Review Based on the Current Literature Over a Year of Pandemic Experience

<sup>1</sup>  Ahmet Riza Sahin, <sup>2</sup>  Burhan Fatih Kocyigit, <sup>3</sup>  Ekrem Aksu, <sup>4</sup>  Burcu Akkok, <sup>5</sup>  Ali Muhittin Tasdogan, <sup>6</sup>  Murat Sahin, <sup>7</sup>  Mahmut Egemen Senel, <sup>8</sup>  Hilmi Erdem Sumbul, <sup>9</sup>  Erdinc Gulumsek, <sup>10</sup>  Mahmut Buyuksimsek, <sup>11</sup>  Deniz Tuncel, <sup>12</sup>  Hamza Sahin, <sup>13</sup>  Ramazan Azim Okyay, <sup>14</sup>  Aysegul Erdogan, <sup>15</sup>  Lutfiye Ozpak, <sup>16</sup>  Ahmet Acipayam, <sup>17</sup>  Celaledin Turgut, <sup>18</sup>  Ismet Cengic, <sup>19</sup>  Dogan Cakan, <sup>20</sup>  Semih Usaklioglu, <sup>21</sup>  Mehmet Kutlu Demirkol, <sup>22</sup>  Omer Mert, <sup>23</sup>  Abdullah Tok, <sup>24</sup>  Abdullah Beyoglu, <sup>25</sup>  Rasit Dilek, <sup>26</sup>  Ali Mesen, <sup>27</sup>  Selma Ates<sup>1</sup>

<sup>1</sup>Department of Infectious Diseases and Clinical Microbiology, Kahramanmaraş Sutcu Imam University Faculty of Medicine, Kahramanmaraş, Turkey

<sup>2</sup>Department of Physical Medicine and Rehabilitation, Kahramanmaraş Sutcu Imam University Faculty of Medicine, Kahramanmaraş, Turkey

<sup>3</sup>Department of Cardiology, Kahramanmaraş Sutcu Imam University Faculty of Medicine, Kahramanmaraş, Turkey

<sup>4</sup>Department of Chest Diseases, Kahramanmaraş Sutcu Imam University Faculty of Medicine, Kahramanmaraş, Turkey

<sup>5</sup>Department of Anesthesiology and Reanimation, Hasan Kalyoncu University Health Sciences Faculty, Gaziantep, Turkey

<sup>6</sup>Department of Endocrinology and Metabolic Diseases, Kahramanmaraş Sutcu Imam University Faculty of Medicine Kahramanmaraş, Turkey

<sup>7</sup>Department of Internal Medicine, Kahramanmaraş Sutcu Imam University Faculty of Medicine Kahramanmaraş, Turkey

<sup>8</sup>Department of Internal Medicine, University of Health Sciences, Adana City Training and Research Hospital, Adana, Turkey

<sup>9</sup>Department of Gastroenterology, University of Health Sciences, Adana City Training and Research Hospital, Adana, Turkey

<sup>10</sup>Department of Medical Oncology, University of Health Sciences, Adana City Training and Research Hospital, Adana, Turkey

<sup>11</sup>Department of Neurology, Kahramanmaraş Sutcu Imam University Faculty of Medicine, Kahramanmaraş, Turkey

<sup>12</sup>Department of Public Health, Kahramanmaraş Sutcu Imam University Faculty of Medicine, Kahramanmaraş, Turkey

<sup>13</sup>Department of Medical Biology, Kahramanmaraş Sutcu Imam University Faculty of Medicine, Kahramanmaraş, Turkey

<sup>14</sup>Department of Thoracic Surgery, Kahramanmaraş Sutcu Imam University Faculty of Medicine, Kahramanmaraş, Turkey

<sup>15</sup>Department of Psychiatry, Kahramanmaraş Sutcu Imam University Faculty of Medicine, Kahramanmaraş, Turkey

<sup>16</sup>Department of Radiology, Acibadem Fulya Hospital, İstanbul, Turkey

<sup>17</sup>Department of Ear, Nose and Throat Diseases, İstanbul Taksim Training and Research Hospital, İstanbul, Turkey

<sup>18</sup>Department of Ear, Nose and Throat Diseases, İstanbul Haseki Training and Research Hospital, İstanbul, Turkey

<sup>19</sup>Department of Urology, Kahramanmaraş Sutcu Imam University Faculty of Medicine, Kahramanmaraş, Turkey

<sup>20</sup>Department of Dermatology, Bezmialem Vakıf University, İstanbul, Turkey

<sup>21</sup>Department of Gynecology and Obstetrics, Kahramanmaraş Sutcu Imam University Faculty of Medicine, Kahramanmaraş, Turkey

<sup>22</sup>Department of Ophthalmology, Kahramanmaraş Sutcu Imam University Faculty of Medicine, Kahramanmaraş, Turkey

<sup>23</sup>Department of Ophthalmology, Konya Kulu State Hospital, Konya, Turkey

**Address for correspondence:** Ahmet Riza Sahin, MD. Kahramanmaraş Sutcu Imam Üniversitesi Tıp Fakültesi, Enfeksiyon Hastalıkları ve Klinik Mikrobiyoloji Anabilim Dalı, Kahramanmaraş, Turkey

**Phone:** +90 344 300 3771 **E-mail:** drahmetrizasahin@gmail.com

**Submitted Date:** January 08, 2021 **Accepted Date:** February 13, 2021 **Available Online Date:** February 23, 2021

©Copyright 2021 by Eurasian Journal of Medicine and Oncology - Available online at www.ejmo.org

**OPEN ACCESS** This work is licensed under a Creative Commons Attribution-NonCommercial 4.0 International License.



## Abstract

On January 7, 2020, it was announced that the Chinese Government isolated a new variant of Coronavirus (SARS CoV-2). Officials reported that populations were not equally affected in terms of the number of cases, severe illness, and death. As of 28 December 2020, 81,000,000 cases have been confirmed globally, and approximately 1,770,000 total deaths have been reported for COVID-19. Besides difficulties of COVID-19 management in the acute stage, long-term consequences of the infection could cause widespread public health problems across the World. This review article aims to examine current literature regarding COVID-19, identify post-illness sequelae, detect patients at risk for sequelae, and provide guidance to management strategies. In the report, long-term pulmonary sequels and systemic problems including cardiovascular, neurological, psychiatric, endocrinologic, nephrological, hematologic, gastrointestinal, dermatologic, etc. of COVID-19 are discussed in accordance with recent scientific publications.

**Keywords:** COVID-19, SARS-CoV-2, long-term care, pulmonary fibrosis, sequelae

**Cite This Article:** Sahin AR, Kocyigit BF, Aksu E, Akkok B, Sahin M, Senel ME, et al. Multisystemic Long-Term Sequelae of Covid-19: A Review Based on the Current Literature Over a Year of Pandemic Experience. EJMO 2021;5(1):6–19

On January 7, 2020, it was announced to the world that the Chinese Government isolated a new variant of Coronavirus (SARS CoV-2).<sup>[1]</sup> As a result of the rapid and uncontrolled epidemic, countries' healthcare systems have shown different reactions in surveillance, diagnosis, and treatment. Officials reported that populations were not equally affected in terms of the number of cases, severe illness, and death.<sup>[2]</sup> Validated, fast, and reliable laboratory testing opportunities are crucial for detecting resources as well as epidemiological studies.<sup>[3]</sup> Currently, the diagnosis of the disease (COVID-19) constituted by SARS CoV-2 is being conducted on the suspected patients through the application of oropharyngeal swab samples and real-time reverse transcription-polymerase chain reaction (RT-PCR) techniques for nucleic acid (RNA) test or occasional by testing stool samples.<sup>[4]</sup> Given the necessity for rapid recognition of new cases and considering the potential inadequacy of COVID-19 tests, accession to the test relied on the presence of the typical symptoms of COVID-19-associated acute respiratory infection (associated cough, fever, and shortness of breath).<sup>[5,6]</sup>

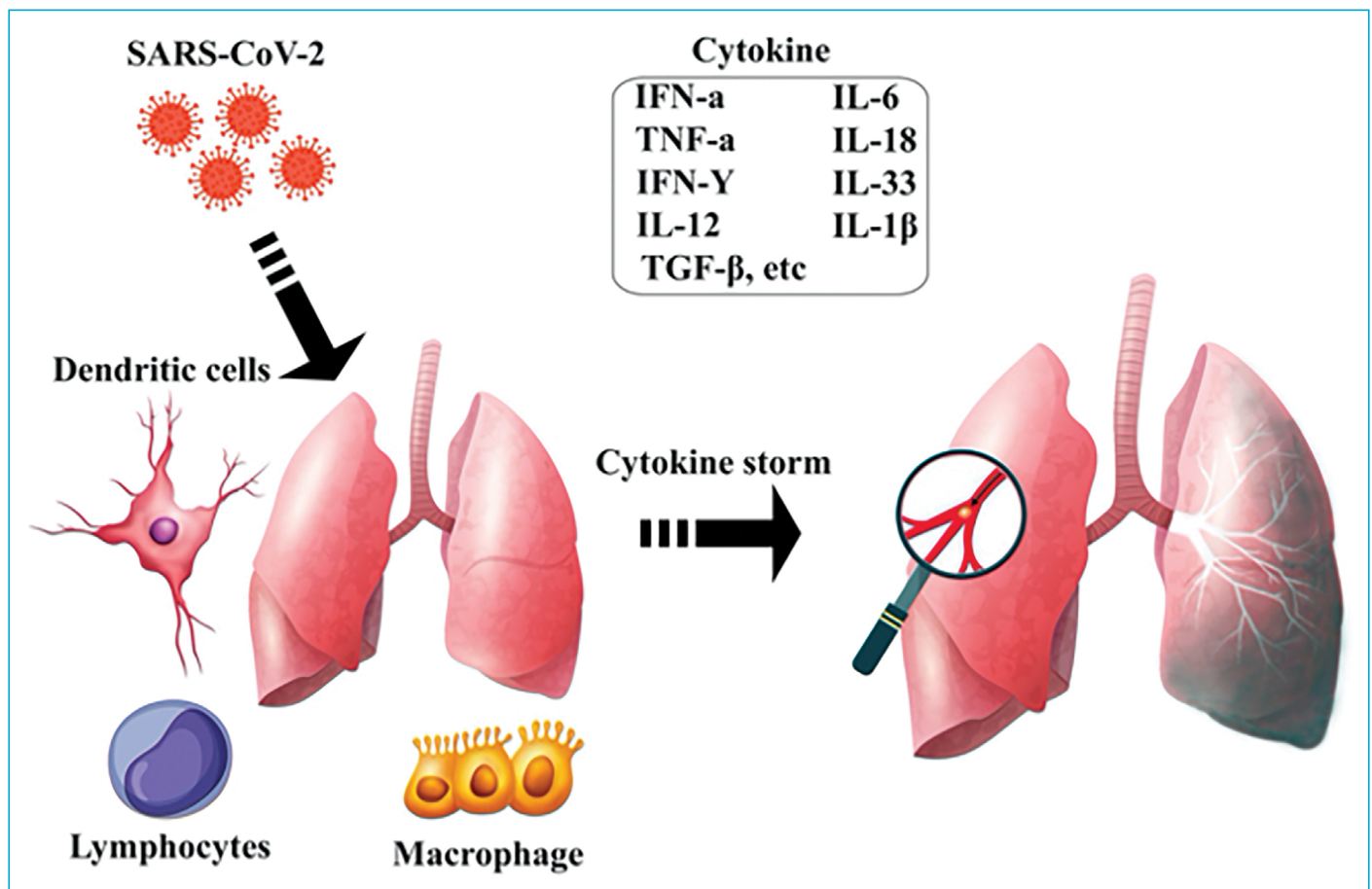
As of 28 December 2020, 81,000,000 cases have been confirmed globally, and approximately 1,770,000 total deaths have been reported for COVID-19.<sup>[7]</sup> The pathogenic mechanisms that engender pneumonia caused by SARS-CoV-2 appear particularly complex. A rapid and well-coordinated immunological response against the viral infection is the initial defense-line. Notwithstanding, the available data in the literature indicate that viral infection can produce an excessive immunological reaction in the host. In some instances, the immunopathology called "Cytokine Storm" occurs, leading to dysfunctional coagulation and deep tissue damage (Fig 1).<sup>[8]</sup> The disease can present itself in a wide variety of clinical courses, ranging from asymptomatic cases to cases with mild or severe pneumonia, some requiring intensive care. Even in uncomplicated (mild) illnesses presenting with fever, muscle pain, and upper respiratory tract symptoms,

mild or severe pneumonia may be present.<sup>[8]</sup> The involvement of organs besides the lungs is a critical aspect of the disease. It is being considered that SARS-CoV-2 is using angiotensin-converting enzyme 2 (ACE2) as its cell receptor. Apart from the lungs, kidneys, gastrointestinal tract, liver, endothelial cells, arterial smooth muscle cells, the organs and systems with high expression of ACE-2 receptors would be predictable targets for SARS-CoV-2 infection (Fig. 2).<sup>[9]</sup> Confirming these findings, an increasing number of articles report extrapulmonary involvement and long-term sequelae of COVID-19.

This review article aims to examine current literature regarding COVID-19, identify post-illness sequelae, detect patients at risk for sequelae, and provide guidance to management strategies.

## Pulmonary Complications

While the COVID-19 pandemic affecting many systems, the most affected one is the respiratory system, and the cases that we encounter mostly occur with viral pneumonia. World Health Organization (WHO) estimates that 80% of the cases are asymptomatic or mild, 20% of them vary in severity with clinical conditions such as respiratory failure, hyperinflammatory response, thromboembolism, and acute respiratory distress syndrome (ARDS).<sup>[10]</sup> Although it is still early to determine the long-term effects of COVID-19, it is predicted that respiratory systems are more likely to get affected, similar to SARS and middle east respiratory syndrome (MERS). In a study investigating the effects of SARS disease, people who had the disease were examined for one year, and it was found that 23% of these patients had impaired lung functions and decreased exercise capacity.<sup>[11,12]</sup> In another study in which early SARS cases were investigated, pulmonary fibrosis findings were detected on computed tomography (CT) in 62% of the cases after 37 days on average.<sup>[13]</sup> Among these patients, it was observed



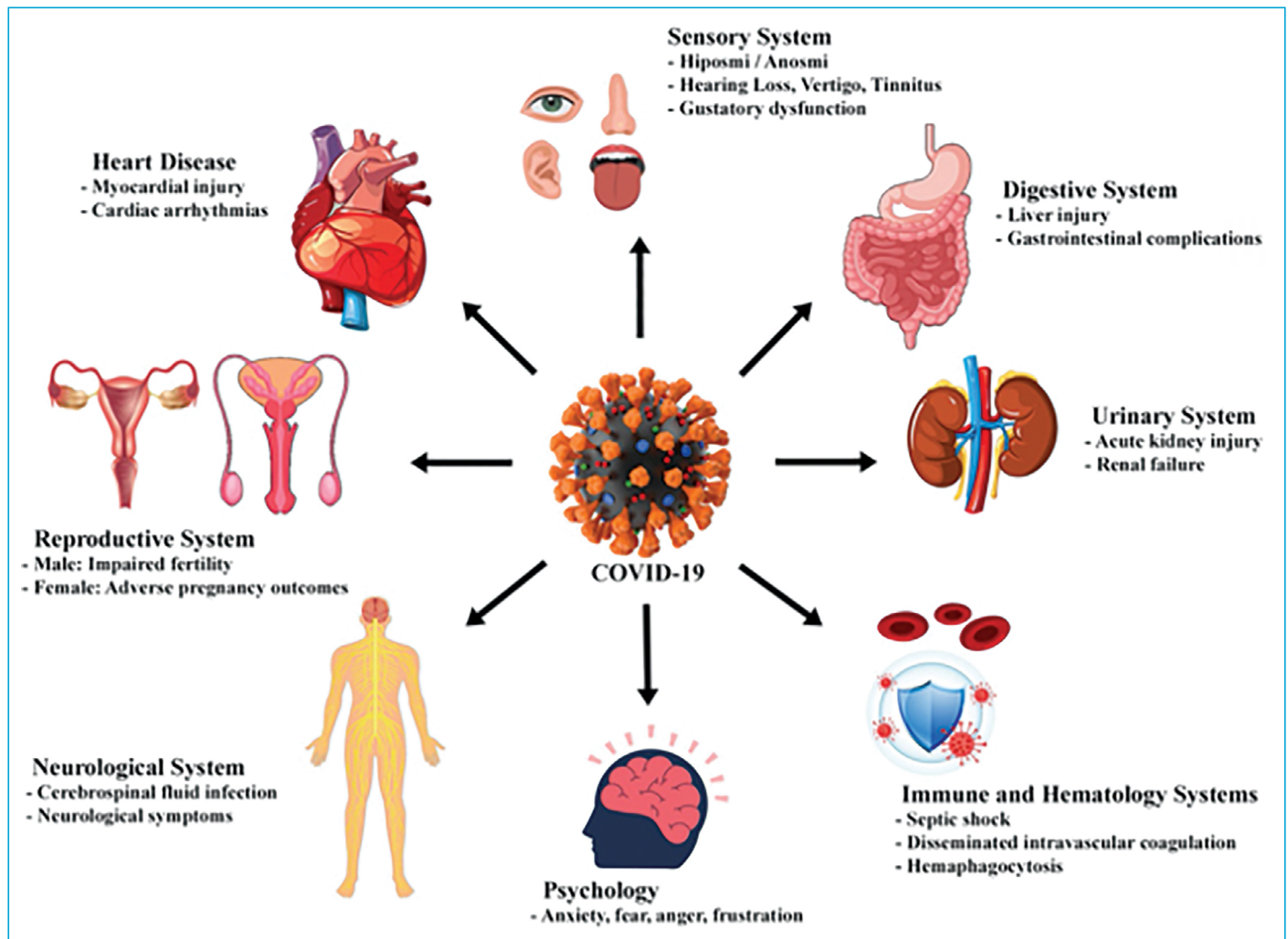
**Figure 1.** The cell types and cytokines contributing to the cytokine storm in SARS-CoV-2 infection.

that patients with a high risk of developing fibrosis were older and had a higher probability of intensive care. In a study involving 36 patients who had MERS and survived, it has been shown that 33% of the patients had radiological findings of pulmonary fibrosis.<sup>[14]</sup>

In the acute phase of COVID-19 pneumonia, lung damage is considered the result of the inflammatory response against viral infection and possible bacterial superinfection. It is also thought that endothelial dysfunction and local thromboembolic events further exacerbate the damages.<sup>[15]</sup> In histopathological examinations, intra-alveolar and interstitial fibrin accumulation and chronic inflammatory infiltrates were detected a few weeks after diagnosis.<sup>[16]</sup> Nevertheless, the remodeling mechanism remains uncertain in the long-term. When the patients' clinical and radiological findings are considered, the long-term effects will most likely emerge as interstitial lung disease and pulmonary vascular diseases. Prolonged cough is a clinical condition that is often observed after treatment. During a study that investigates 90 cases of COVID-19, it has been observed that 94% of patients who undertook lung CT scans after 24 days of the disease had alterations in their lungs in the form of frosted glass.<sup>[17]</sup> In another study of 55

patients evaluated three months after discharge, radiological abnormalities were detected in 70.9% of the patients and lung function abnormalities in 25.4%. Among the detected dysfunctions, decreased lung diffusing capacity for carbon monoxide (DLCO) was the most common.<sup>[18]</sup>

At this stage, the most wondered question is whether these patients with lung CT abnormality after the treatment will develop fibrosis in the lungs in the future, as in SARS and MERS. It will be convenient to benefit from the experiences of previous coronavirus outbreaks in estimating its frequency. These studies also indicate that COVID-19 patients who needed intensive care and recovered will face pulmonary fibrosis risk in the future. Another uncertain situation is whether these patients will develop bronchiectasis after infection. The other most prevalent clinical problem we encounter during the disease period of COVID-19 is thromboembolism. COVID-19 has a high risk of venous thromboembolism mainly due to endothelial damage.<sup>[19,20]</sup> Patients who experienced acute pulmonary embolism during their illness should be followed up closely for pulmonary hypertension afterward. Simultaneously, thromboembolism should be considered in stabilized patients after the treatment and have sudden clinical deterioration. There are



**Figure 2.** The systems affected by COVID-19.

opportunistic infections in clinical practice that we can see as complications of the immunosuppressive therapies we use during covid treatment. It is not a direct effect of the virus that we can observe after Covid. In a postmortem study conducted after the SARS outbreak, invasive aspergillus and Cytomegalovirus (CMV) infections were detected with a frequency of 15 percent.<sup>[21,22]</sup> These infections should also be kept in mind in the post-COVID period. When the global burden of disease is considered, fibrotic lung illnesses can become a crucial public health issue. In this respect, patients should be delicately followed by clinicians after their COVID-19 treatment processes.

### Cardiovascular Complications

The primary entrance point of SARS-CoV-2 into the body is the ACE 2 receptor. The ACE 2 receptor is found not only in respiratory system epithelium cells but also in cardiac myocytes and endothelium cells of the vascular system. Therefore, it is apparent that the organs of the cardiovascular

system are also targets of the disease. The direct cytotoxic effect of the virus on the respiratory epithelium, myocyte, and endothelium cells is the primary mechanism in the development of the clinical picture.

Besides that, disruption of the regulatory effect of the ACE 2 receptor on the renin-angiotensin system, kinin-kallikrein system, complement system, and increased inflammation and hypoxia are other mechanisms contributing to the formation of clinical cascade.<sup>[23]</sup> Approximately between 7-20 percent of total Covid-19 cases have cardiovascular involvement during the acute illness period. Cardiovascular involvement, which can be seen during the acute disease period, can clinically present as myocarditis, pericarditis, arrhythmic events, cardiac insufficiency, venous thromboembolic conditions, coronary ischemia, cerebral ischemia.<sup>[24,25]</sup> The presence of cardiovascular involvement is associated with increased mortality rates in the early disease period. As the COVID-19 disease came into existence recently, the effect of the already-existing cardiovascular impairment on



long-term continuity and mortality rates remains uncertain. Notwithstanding, case reports may shed light on the medium and long-term impact. A study conducted by Konar et al.<sup>[26]</sup> revealed that systolic or diastolic dysfunction due to cardiac injury continues in the medium term in those who survived the acute phase. In a magnetic resonance imaging (MRI) study conducted with patients with a history of hospitalization and who went through intensive care due to COVID-19, it was observed that inflammatory involvement in the myocardium continued on the 70<sup>th</sup> day.<sup>[27]</sup> In another MRI study, the detection of residual myocardial inflammation on young athletes with Covid-19 raises concerns about the possibility and consequences of long-term permanent myocardial dysfunction.<sup>[28]</sup> Increased inflammation in the myocardium can contribute to the development of permanent arrhythmias associated with increased mortality and morbidity, such as electrical atrial fibrillation and atrial remodeling, which can be triggered by hypoxemia and myocyte damage.<sup>[29]</sup> In the acute phase, increased inflammation, endothelium dysfunction, and thrombosis have been detected in the pulmonary vascular bed.<sup>[30,31]</sup> These circumstances may cause permanent damage to a certain number of patients and trigger pulmonary hypertension development. As a result, during the COVID-19 pandemic, patients exposed to previous cardiovascular diseases, especially in the acute disease period of COVID-19, should be closely monitored for permanent cardiovascular disorders that may develop in the long-term, which is also associated with higher mortality and morbidity.

### Post Covid-19 Rehabilitation

The long-term sequelae of the critically affected COVID-19 cases are currently unknown. However, potential sequelae can be envisaged based on a large quantity of literature similar to post-illness disorders, including ARDS and SARS.<sup>[32]</sup> Rehabilitation strategies should be an integral part of COVID-19 management. For COVID-19 patients, rehabilitation should be initiated during the early phase of the illness and continued with long-term rehabilitation programs after discharge.<sup>[33]</sup> A comprehensive pulmonary rehabilitation approach will probably be required due to lung complications developing in this patient group. Pulmonary rehabilitation programs, including inspiratory muscle strengthening, exercise training, drainage methods, and breathing exercises, will benefit the appropriate group of patients.<sup>[34]</sup> Pulmonary rehabilitation programs should be customized by considering advanced age, obesity, multiple diseases, and complications.<sup>[35]</sup> Patients should be followed throughout the pulmonary rehabilitation process using various technological devices.<sup>[36]</sup> Patients who are hospitalized in the intensive care unit

mostly remain stationary in a prone position. This situation may cause muscle atrophies, contractures, impaired balance and gait, dysphagia, and consequently, limitations in daily living activities. Patients should be evaluated during hospitalization to prevent these complications, and appropriate post-discharge rehab strategies should be developed.<sup>[36]</sup> Another aspect that should be emphasized in rehabilitation is that this patient group may encounter neurological diseases such as critical illness myopathy, critical illness polyneuropathy, ataxia, and cerebrovascular disease.<sup>[32,37]</sup> Furthermore, the frequency of neurological disorders increases in accordance with disease severity. This factor should be considered during the planning of rehabilitation strategies for patients showing neurological effects of COVID-19.<sup>[38]</sup>

In the forthcoming period, rehabilitation physicians will encounter various problems associated with COVID-19 sequelae and will need to rapidly develop rehabilitation strategies. Careful preparation and planning could be significant factors to limit the sequelae from Covid-19.

### Radiological Findings of Covid-19 Pneumonia Sequelae

Typical thorax computed tomography (CT) scan findings of early Covid-19 pneumonia are peripheral patchy and nodular ground-glass opacities (GGOs) in both lungs. The GGOs may be accompanied by consolidation, interlobular and intralobular septal thickenings, pleuroparenchymal fibrotic retractions, nodular appearances with reversed halo sign. In advanced cases, crazy-paving pattern can be observed. Lung involvement predominantly occurs in the posterior parts of the lower lobes.<sup>[39,40]</sup>

Since COVID-19 is a relatively new disease, it has not been possible to observe long-term sequelae. In a short-term study with 149 patients, it was observed that COVID-19 lesions in CT scans completely regressed in 53% of patients three weeks after discharge from the hospital. However, it was realized that GGOs and fibrous retractions continued in 47% of the patients, and the duration for regression of the lesions was prolonged in the elderly patients.<sup>[41]</sup> The main limitation of this study is that critically ill patients were not included.

In a 2016 study conducted on SARS (severe acute respiratory syndrome) caused by a variant of Coronavirus, Wu et al.<sup>[42]</sup> reported that GGOs and residual lung lesions in the form of interlobular and interlobular septal thickening could be observed permanently after years from SARS recovery. In our clinic, it was observed that during the early four-week recovery period of moderate and severe COVID-19 patients discharged from the hospital, GGOs turned into thick fi-

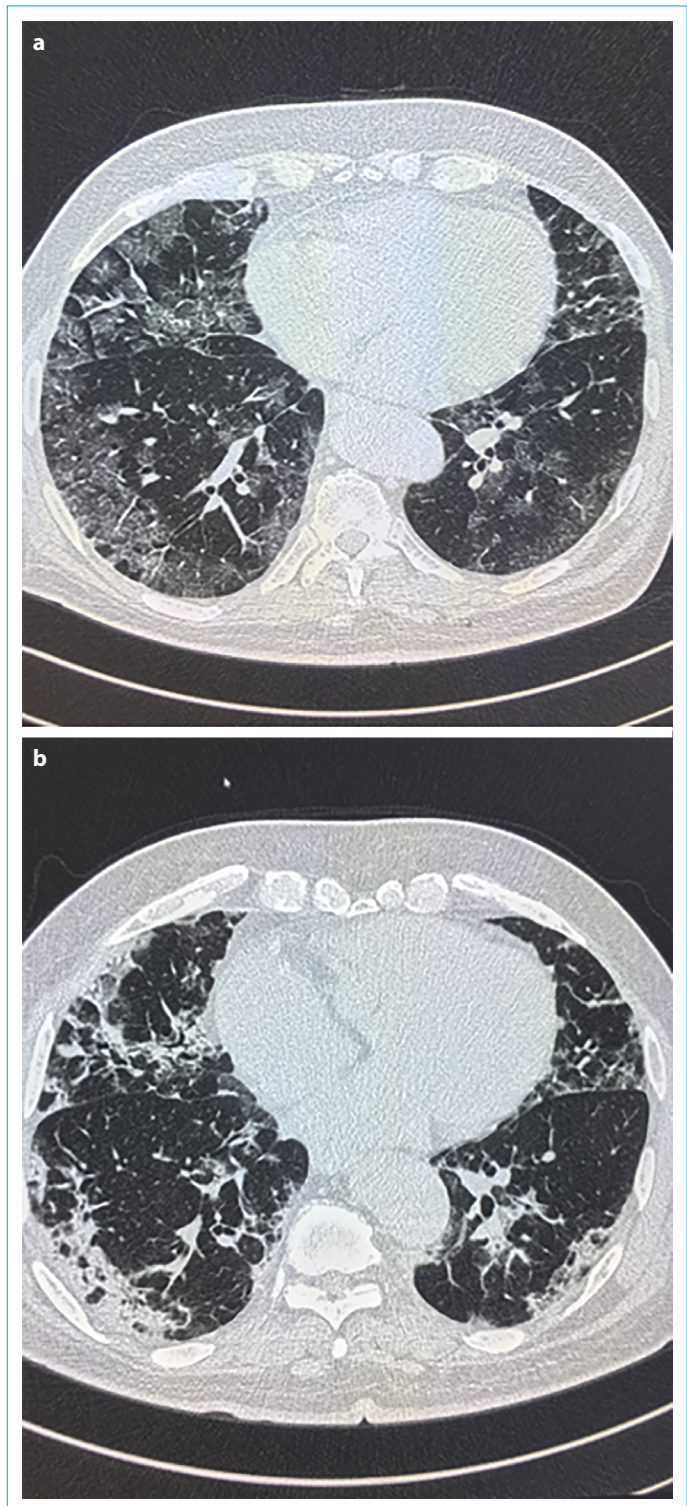
brous retractions and bands (Fig. 3 a, b and Fig. 4 a, b). In some of the clinically mild cases, it was noticed that GGOs have dulled but not entirely disappeared. Since there is no long-term study for COVID-19, it is unclear whether the fibrotic sequelae will be fully resorbed and how they will affect the lung functions.

### Neurological Problems

As we have a better understanding of COVID-19 in the last nine months, it has been revealed that a significant group of patients was also experiencing neurological symptoms in addition to the conditions described above. As expected, most of these neurological symptoms were identified in the early period of the infection; thereby, there is not enough information in the literature about the long-term neurological effects of the disease.

Neurological involvement in COVID-19 patients can occur solely or couple with respiratory system involvement.<sup>[43]</sup> It is estimated that at least 30% of these patients accompanied by neurological symptoms and findings.<sup>[44]</sup> 25% of these are assumed to be associated with the central nervous system (CNS).<sup>[45]</sup> The most common symptoms are headache, nausea, and vomiting. Moreover, vertigo, sleep disorders, myalgia, seizures, and changes in consciousness have also been reported. The earliest neurological findings are smell and taste disorders.<sup>[46,47]</sup> While the majority (85-88%) of the mild and moderately affected COVID-19 patients were accompanied by smell and taste disturbance, this rate decreased to 5-6% in moderately to severely affected patients.<sup>[45]</sup> The neurological complications of COVID-19 infection can be categorized into CNS and peripheral nervous system complications. While viral meningitis/encephalitis, acute disseminated encephalopathy, cerebrovascular disease, epilepsy, and spinal cord damage are related to CNS problems; hyposmia (disturbance of smelling sense), hypogeusia (disturbance of tasting sense), Guillain-Barré Syndrome and its variants are the complications are related to the peripheral nervous system (PSS). Studies have put forth various potential pathophysiological mechanisms related to how COVID-19 infection affects CNS and PSS. It is assumed that viral meningitis develops by direct invasion of the CNS, hyposmia, and hypogeusia by direct invasion of the PSS. It has been reported that encephalopathy and cerebrovascular diseases occur as a result of systemic responses such as hypoxia, coagulopathy, and inflammatory response. Acute disseminated encephalomyelitis, acute necrotizing encephalopathy, acute necrotizing myelitis, and Guillain-Barré Syndrome are thought to occur as post-infectious as a result of immune dysfunction.<sup>[45,46]</sup>

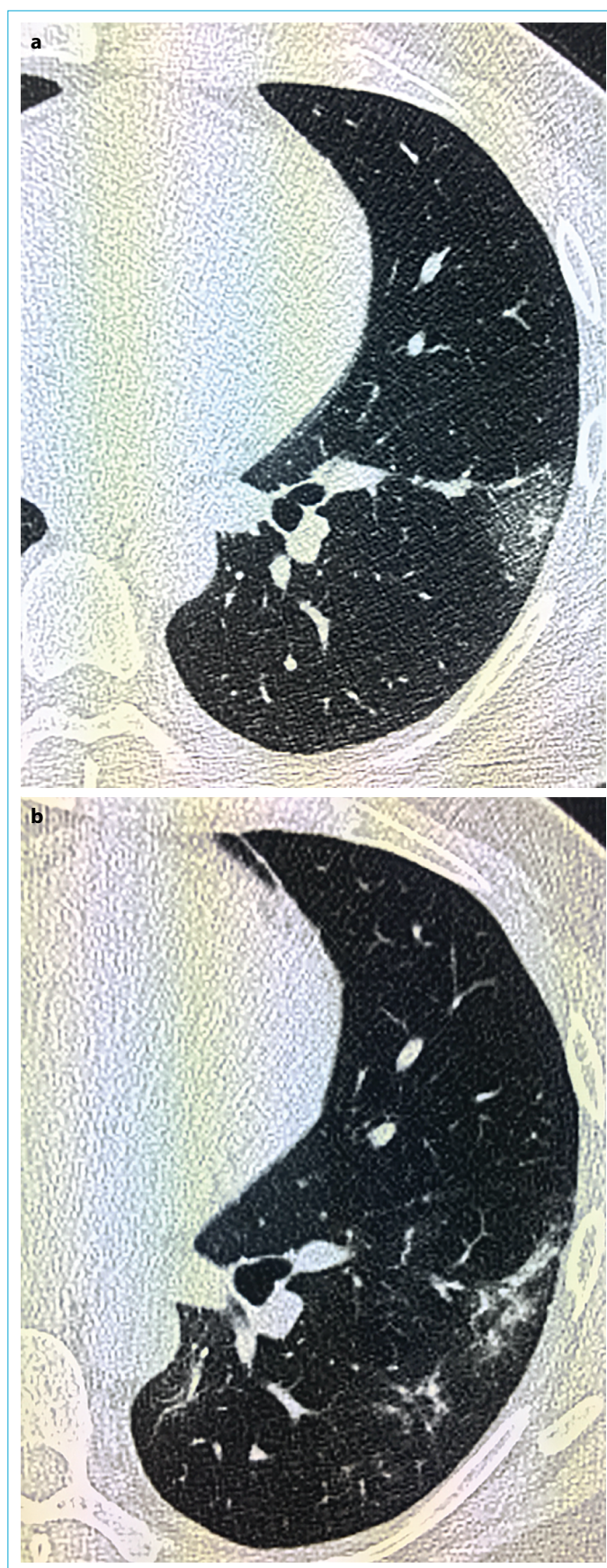
As a result of these mechanisms, the existing neurological disease probably will exacerbate, or a new neurological



**Figure 3.** During hospital admission (a). 25<sup>th</sup> day of discharge (b).

picture will emerge in COVID-19 survivors. This risk may appear as long-term neurological involvement in COVID-19 patients. For example, it was detected that one-third of the COVID-19 patients who were discharged had cognitive impairment and motor deficits.<sup>[48]</sup> There is strong evidence showing a high risk of neurological diseases such as Al-





**Figure 4.** During hospital admission (a). 28<sup>th</sup> day of discharge (b)

zheimer's Disease (AD) after COVID-19. The most prominent evidence is that NLRP3 inflammasome associated inflammation impairs the beneficial immune function in the brain, causing accumulation of neurodegenerative peptides such as fibrillary amyloid-beta.<sup>[49]</sup> Under these circumstances, it is thought that ADs will result in functional deterioration or disease progression. COVID-19 can disrupt the blood-brain barrier (BBB), leading to many small punctate ischemias. Patients may show signs of impaired memory and attention after discharge. Therefore, COVID-19 patients, especially those with a severe course, should be followed up by performing neurocognitive evaluations at specific periods after discharge. Other potential long-term neuropsychiatric and neurocognitive findings are depression, obsessive-compulsive disorder (OCD), psychosis, and Parkinson's disease.<sup>[50]</sup> In recent publications, evidence has been presented that there is a new syndrome called Post COVID-19 Neurological Syndrome (PCNS) consisting of patients accompanied by prolonged muscle weakness and other forms of myopathy.<sup>[51]</sup> COVID-19 can cause ischemic cerebrovascular changes even in young patients by leading to endothelium dysfunction and coagulation disorder (DIC). Ischemic stroke risk in advanced cases has been identified as 6%.<sup>[44]</sup>

This risk applies to both arterial and venous cerebrovascular events. During the subacute period, cases of Guillain-Barré syndrome and Miller-Fisher syndrome were reported 3-10 days after COVID-19 symptoms came into existence.<sup>[45-47]</sup> Rhabdomyolysis may develop as a late complication in COVID-19 patients. Therefore, renal values and muscle enzymes should be carefully monitored during the course of COVID-19 infection. Headache can be observed in up to 40% of patients, but there is no thorough study of its type, frequency, and long-term effects.<sup>[52]</sup> A comprehensive study from Belgium and the Netherlands examined asymptomatic cases or patients with mild symptoms by tracking 112 hospitalized and 2001 outpatients and detected that COVID-19 patients have suffered from muscle pain, dizziness, headache, fatigue, and anosmia for months.<sup>[51]</sup> The fatal and severe sequelae of the COVID-19 disease have urged clinicians to laboratory and screening studies with the concern of making a rapid diagnosis. Neurological evaluation is being neglected in this patient group. As a result, detection of possible early and long-term neurological involvement is being delayed, treatment of urgent neurological conditions such as GBS is interrupted. Therefore, the neurological examination must be added to the evaluation algorithms of COVID-19 patients.

### Psychiatric Problems

COVID-19 has led to the emergence of a new psychiatric diagnosis called "Covid Stress Syndrome". The syndrome

described by Taylor et al.<sup>[53]</sup> consists of fear of transmission, anxiety regarding the socioeconomic status, fears associated with dissemination of virus by strangers, traumatic stress symptoms (nightmares, COVID-19 related imaginations), compulsive control, and reassurance-seeking behaviors. While pre-pandemic contamination fear, social distance, and attention to hand hygiene were associated with an increase in compulsive handwashing behavior, it did not predict coronavirus anxiety.<sup>[54]</sup>

As a consequence of the pandemic, it has been reported that psychological well-being decreased. In contrast, an increase of anxiety and depression scores were observed in the general population compared to the pre-corona era.<sup>[55]</sup>

The quarantine method implemented in the control of the epidemic brought significant psychosocial problems. Significant mental results occur during the quarantine period of 1 week or above. The frequency of anxiety and depression in individuals in quarantine has been reported as 22.4-70.78% and 26.47-30.5%.<sup>[56,57]</sup> In addition, an increase in stress-related disorders / post-traumatic stress disorder (PTSD), anger, child abuse, and domestic violence has been reported.<sup>[58]</sup> Child maltreatment has been particularly associated with parents who lost their job and had depression.<sup>[58]</sup> A longer quarantine period was not found to be associated with depression and PTSD in a local study, while fear level and decreased sleep were shown as the most important risk factors for psychological distress.<sup>[59]</sup> In a cohort study of 62,354 patients diagnosed with COVID-19, the frequency of any psychiatric disorder was 18.1%. In contrast, 5.8% had faced a new additional psychiatric issue in the evaluation performed 14 to 90 days after COVID-19 diagnosis. It is found that those who pulled through COVID-19 have a higher incidence of psychiatric disorders, dementia, and insomnia when compared with other infections.<sup>[60]</sup> In the evaluation of those who had the disease one month later, the frequency of obsessive-compulsive symptoms was reported as 20% and insomnia as 40%.<sup>[60]</sup>

In a study carried out by Tomasoni et al.,<sup>[61]</sup> it was reported that approximately one-third of the patients were diagnosed with anxiety/depression on average 46 days after getting infected by COVID-19. The frequency of PTSD is between 6.5-31% in patients who have fully recovered via COVID-19 treatment.<sup>[62-64]</sup> In another study, PTSD is the most commonly reported condition among those who had Covid 19. Gender, stigmatization, and prolonged symptoms (dyspnea, chest pain, fatigue) are predictors of PTSD symptom severity.<sup>[65]</sup> Patients who had or having Covid 19 feel isolated more frequently.<sup>[66]</sup> The disease has been associated with loneliness, depression, and suicidal thoughts.<sup>[67]</sup> It has been reported that significant cognitive deficits developed

in COVID-19 patients who recovered, and these outcomes were independent of age, gender, education, ethnicity, income, and previous medical illnesses. A 10-year-old regression in global performance and 8.5 points decrease in intelligence coefficient were reported in the ventilator-dependent subgroup.<sup>[68]</sup> Besides, it has been reported that COVID-19 patients experience delirium, agitation, changes in consciousness, manic symptoms, and decreased memory capabilities.<sup>[69]</sup> Cases of psychotic episodes and catatonia associated with COVID-19 have been reported.<sup>[70-72]</sup>

Psychiatric sequelae that occur in COVID-19 patients are a significant cause of disability. The isolation and job losses that are the main consequences of the pandemic can affect the frequency and severity of mental disorders due to various psychosocial factors. We contemplate that the establishment of post-covid mental support units and fast and early treatments can reduce psychiatric sequelae.

### Endocrinological Problems

Although there are morbidities affecting many systems in COVID-19, the endocrine system is one of the frequently affected systems. The thyroid gland is often affected by other diseases. Thyroid functions are affected in many hospitalized patients. Especially in critically ill patients, a condition that we call euthyroid syndrome occurs due to some reasons such as inhibition of 5' mono-deiodinase, increased cortisol levels in response to the disease, and escalation of some cytokines as a result of inflammation. In the euthyroid syndrome, defects in function tests such as decreased serum T3 levels, increased or decreased serum T4 values, and decreased TSH values can be observed. In a study conducted on Covid patients, it was shown that approximately 27.5% of the patients had euthyroid syndrome. It was noted that the syndrome is particularly correlated with the severity of the COVID disease.<sup>[73]</sup>

One of the most frequently reported situations pertinent to Covid is subacute thyroiditis cases. Conditions accounted for subacute thyroiditis include viral infections or postviral inflammatory processes. Often there are signs of a viral infection beforehand.

Some patients with COVID-19 may suffer subacute thyroiditis as an initial symptom, or it can be observed as early as one week after the onset of symptoms or in the late period after infection.<sup>[74-76]</sup> In some case reports, it has been reported that COVID-19 infection may trigger underlying thyroid diseases and cause thyrotoxic attack in the patient who is followed up due to remission of Graves, or in patients who do not have a previous history of thyroid can be diagnosed with Graves disease.<sup>[77,78]</sup> The detection of the ACE-2 receptor used by Covid to infiltrate into the cell dur-



ing the thyroid tissue samples in the pathological examination of thyroidectomy may explain why the thyroid gland is so activated in COVID-19 disease.<sup>[79]</sup> In the post- COVID period, a case of postpartum thyroiditis has been reported in a pregnant woman other than subacute thyroiditis. This issue should be kept in mind in the post-pregnancy period, especially in pregnant women who had COVID-19.<sup>[80]</sup>

We know that COVID-19 infection is more severe in some chronic diseases and leads to a higher mortality rate. Diabetes mellitus is one of those diseases. In a recent comprehensive meta-analysis, it was observed that the mortality due to COVID-19 in diabetic patients was two times higher and that serious covid infection was observed more frequently in these patients.<sup>[81]</sup> It has been reported that COVID-19 infection precipitates the acute complications of diabetes in diabetic patients, and it has been reported that patients apply to healthcare institutions due to diabetic ketoacidosis and diabetic hyperosmolar coma. These conditions are believed to contribute to the mortality of diabetic patients.<sup>[82,83]</sup> In addition to the fact that diabetes patients are more vulnerable to covid, the disease has effects on diabetes.

The ACE-2 receptor to which the Coronavirus is being attached is found in structures such as pancreatic beta cells, adipose tissue, and kidney. These interactions play a crucial role in the pathogenesis of diabetes. One of the pieces of evidence supporting this finding is that new-onset diabetes more common among COVID-19 patients. Thereby, in the future, we can observe an increase in the risk of diabetes in patients who had COVID-19.<sup>[84]</sup> Another case report supporting this situation is the development of insulin-dependent diabetes in a young patient with covid. Although the patient had only a mild risk of type-1 DM due to his HLA antigens, diabetes still advanced, and antibody positivity was not observed.<sup>[85]</sup>

In some autopsy studies conducted on COVID-19 patients, it has been shown that other endocrine organs might get affected. In a study in which the autopsy of 28 patients with Covid was evaluated, it was reported that adrenals were affected in 46% of the patients, necrosis in 7 cases, cortical lipid degeneration in 4 cases, hemorrhage in 2 cases, and focal adrenalitis in 1 case.<sup>[86]</sup> Primary adrenal insufficiency was reported in a patient with a diagnosis of COVID-19, and it was assumed that this situation might be a result of the thrombo-inflammatory effects of COVID-19.<sup>[87]</sup> Another example of adrenal involvement is the adrenal hemorrhage cases reported in covid patients. In another case report, adrenal infarction due to COVID-19 infection has been reported.<sup>[88-91]</sup>

Although there is not much publication on hypophysis and hypothalamic involvement in COVID-19 patients, the occurrence of diabetes insipidus in a patient with COVID-19

infection and its improvement with vasopressin have shown that there is central diabetes insipidus diagnosis.<sup>[92]</sup> The authors thought that this involvement developed as a result of hypoxic encephalopathy. Therefore, we may encounter insufficiencies due to possible hypophysis and hypothalamic involvement in these patients in the future.

## Hematological Problems

Hematological issues are quite common among the patients with COVID-19 infection. During the admissions to the health institution, the patients infected with COVID-19 usually have leucopenia, lymphopenia, or elevated peripheral neutrophil levels.<sup>[93]</sup> Despite venous thromboembolism (VTE) is occasionally mortal, it is a curable syndrome. Deep vein thrombosis (DVT) that develops in the deep veins of the lower extremities can lead to pulmonary embolism. Nowadays, DVT and pulmonary embolism are being referred to by the common name VTE. Recently, it has been recognized that inflammation plays a significant role in the development of VTE. COVID-19's course, accompanied by excessive inflammation, platelet activation, endothelial dysfunction, and stasis leads to an important prediction for VTE development. Interestingly, VTE has been reported to occur even in COVID-19 cases under therapeutic anticoagulation. These findings show the thrombogenic character of COVID-19. The risk of developing VTE during COVID-19 ranges from 19% to 25%.<sup>[94]</sup> A study conducted in China reported that 40% of COVID-19 patients are at high risk for VTE.<sup>[95]</sup> During a study performed in Spain where prophylactic heparin was applied to 156 COVID-19 patients, 23 people (14.7%) had asymptomatic DVT. Furthermore, only one of the patients with DVT had a proximal variant, whereas others were distal DVT, and bilateral DVT was detected in seven (4.5%) cases.<sup>[96]</sup> The existing data that we have reveals the close association of COVID-19 with susceptibility to hypercoagulability. A retrospective analysis of 21 death cases in COVID-19 patients shows that 71% of patients who lost their lives due to disease have also developed DIC. DIC emerged four days after the hospitalization on average. Patients that survived COVID-19 had DIC incidence of 0.6 percent.<sup>[97]</sup> The evidence suggests that acute coagulation disorders and DIC are common in severe SARS-CoV-2 infection cases, and acute coagulation disorders and DIC are significant risk factors for increased in-hospital mortality.

Therefore, particular attention should be given to the early diagnosis and treatment of these acute hematologic conditions to improve patient survival rates.<sup>[98,99]</sup>

## Gastroenterological Problems

At present, there is very limited data on the impact of COVID-19 infection on gastrointestinal (GI) functions.

In a retrospective study conducted in Wuhan, China, it has been shown that GI symptoms were not common among investigated 1099 patients; only 5% of the patients experienced nausea and vomiting, while 3.8% of patients had diarrhea.<sup>[93]</sup> (1). With that said, a significant proportion of COVID-19 patients who had atypical clinical pictures who applied to the hospital had GI symptoms.<sup>[100]</sup> In a separate study, it was shown that test results for circulating levels of liver function such as serum transaminases, bilirubin, LDH, and prothrombin time (PT) were significantly higher in COVID-19 patients admitted to the intensive care unit compared to patients followed in the service section.<sup>[101]</sup> Similar results were confirmed by Wang et al.<sup>[102]</sup> In a study of 138 COVID-19 patients without chronic liver disease admitted to the intensive care unit. The COVID-19 pandemic also causes significant problems in the management of patients with a liver transplant. Transplant recipients are more susceptible to SARS-CoV2 infection, and the course of the disease is more severe in that particular patient group.<sup>[103]</sup> In a case report, it has been reported that multiple nosocomial infections have been developed rapidly during a short hospital stay in a transplant recipient with COVID-19.<sup>[104]</sup> Studies have shown that SARS-CoV-2 infects the GI tract through angiotensin-converting enzyme II, which is expressed in the ileum and colon enterocytes. Viral RNA was also isolated from stool samples of COVID-19 patients, which increased the anxiety of transmission through a fecal-oral route, in addition to droplet transmission.<sup>[105]</sup> A systematic meta-analysis showed that 10% of the patients applied with sole GI system symptoms without any respiratory symptoms. Moreover, patients who applied with GI system involvement have received delayed diagnosis alongside having a tendency to have a worse disease process.<sup>[106]</sup> As a result, an increase in morbidity and mortality can be observed in the GI system due to COVID-19 infection. Among these patients in which GI symptoms and liver damages are not rare, cases with COVID-19 with existing GI system disease should be examined and followed delicately.

### Nephrologic Problems

Kidneys are among the most susceptible extrapulmonary organs to COVID-19, especially in severe patients.<sup>[107]</sup> Retrospective studies of patients affected by the SARS outbreak that erupted in 2013 have shown that kidney damage is mainly characterized by tubular damage, increased serum creatinine, and urea nitrogen concentrations. A recent study of 59 COVID-19 patients (approximately 50% had severe sickness) showed that mild proteinuria was the most common kidney abnormality in these patients.<sup>[108]</sup> In addition, approximately 30% of these patients also had high urea nitrogen levels, and almost 20% had elevated serum

creatinine levels.<sup>[109]</sup> Acute kidney injury (AKI) development among COVID-19 patients has been reported at substantially varying rates ranging from 0.1% to 29% in different studies, and there is no consistency between studies. This variability may be attributed to the fact that the AKI mechanism engendered by COVID-19 is not yet understood sufficiently.<sup>[93,110,111]</sup> It is considered that the virus binding to the ACE-2 receptor, which is highly expressed in renal tubules, causes glomerulopathy, acute tubular necrosis, and protein leakage in the Bowman Capsule. AKI may also be considered as a result of both hypoxia caused by respiratory distress syndrome (RDS) and septic shock caused by SARS-CoV-2.<sup>[112]</sup> Autopsy researches has shown that renal endothelium is affected and may be accounted for proteinuria.<sup>[113]</sup> SARS-CoV-2 particles in renal endothelial cells may also suggest viremia as a possible inducer of renal endothelial damage resulting in AKI.<sup>[114]</sup> Since COVID-19 is a relatively new disease, we continue to observe long-term sequelae. In a recent large meta-analysis, the prevalence of pre-existing chronic kidney disease (CKD) in COVID-19 patients was 5.2%. The most common renal complication was electrolyte disturbances (in particular hyperkalemia) with an incidence of 12.5% followed by AKI with an incidence of 11.0%; groups with a higher prevalence of CKD had a higher incidence of AKI, and 6% received renal replacement therapy.<sup>[114]</sup> Those with nephrological damage such as COVID-19-related AKI, especially during the acute illness period, have a higher risk of developing progressive CKD subsequent to resolution of the viral infection. These patients should be regularly monitored for permanent nephrological diseases that may develop in the long-term and are associated with increased mortality and morbidity.

### Pneumothorax

COVID-19 mainly affects the lungs and causes typical symptoms such as fever, cough, and shortness of breath. Pneumothorax (PNX) is a rare condition in computed tomography captured during the initial evaluation.<sup>[115–117]</sup> In COVID-19, PNX mostly emerges due to pre-existing lung disease such as pneumonia, but severe strain during persistent cough can also cause Pneumothorax.<sup>[118]</sup> The studies on COVID-19 patients show that only 1% of the patients have Pneumothorax during the application for hospitalization. It can emerge in 2% percent of patients that require hospitalization, and the rate of PNX was reported to be 15% in patients ventilated due to barotrauma.<sup>[119]</sup> Dyspnea is a common symptom of severe COVID-19 pneumonia and pneumothorax. It should be kept in mind that acute deterioration with rapid oxygen desaturation in a COVID-19 patient may indicate pneumothorax. Clinically, in cases where pneumothorax is suspected, the exact diagnosis is made

through posteroanterior chest radiography. The development of pneumothorax is a severe prognostic indicator during coronavirus infection.<sup>[119–122]</sup>

Tube thoracostomy should be performed effectively and rapidly in patients diagnosed with pneumothorax. Recently, SARS-CoV-2 viral RNA has been detected in pleural fluid during autopsies.<sup>[123,124]</sup> Therefore, protective equipment should be provided to clinicians for aerosol-generating procedures during chest drain insertion. As new generation digital drainage systems can be used, it is recommended to connect the drainage circuit to the wall extraction unit after tube thoracostomy and use filters to curb viral spread to reduce the risk of contamination.<sup>[125,126]</sup> In spontaneous pneumothorax, the recurrence rate after tube drainage in the first episode is 10-21%, after the second episode is 50%, and after the third episode, it reaches 80%. A rise in the frequency of PNxis was also predicted in patients who underwent oxygen therapy and/or tube thoracostomy during Covid 19 disease. Therefore, cases developing PNx during COVID-19 should be followed closely and delicately.

## Ophtalmology and COVID-19

It is known that Coronaviruses cause a wide range of ocular complications, from anterior segment pathologies such as conjunctivitis and anterior uveitis to vision-threatening conditions such as retinitis, optic neuritis, choroiditis, and retinal vasculitis.<sup>[127]</sup> ACE2, the binding receptor for SARS CoV-2 (COVID-19) to enter host cells, is located in the conjunctiva and makes the eye a desirable entry site for Covid.<sup>[128]</sup> So far, ocular involvement of SARS CoV-2 has been reported as an early indicator of the infection in many cases.<sup>[129,130]</sup> It is also considered to be an indicator of severe COVID-19.<sup>[131]</sup> Clinical findings of ocular COVID-19 is compatible with acute follicular conjunctivitis alongside conjunctival hyperemia, chemosis, follicular reaction under the lid.<sup>[132,133]</sup> In a study, 12 of 38 clinically confirmed COVID-19 cases (31.6%) reported acute conjunctivitis symptoms, yet only two patients were positive after collection of conjunctival samples and nasopharyngeal swabs.<sup>[131]</sup> Posterior segment ocular involvement has not yet been reported in COVID-19, but retinal abnormalities such as retinal vasculitis, retinal degeneration, and blood-retinal barrier disruption have been reported in previous CoV infections.<sup>[134]</sup> Marinho et al.<sup>[135]</sup> reported that there were hyperreflective lesions compatible with the ganglion cell layer and inner plexiform layer at retinal nerve layer infarction in optical coherence tomography (OCT) taken ensuing the symptoms of 12 adult COVID-19 patients disappeared. However, the results of this study were later examined by other researchers and reported that the OCT findings belong to normal healthy vascular structures.<sup>[136]</sup> In a study with op-

tical coherence tomography angiography (OCTA) on 80 COVID-19 patients and 30 control group members, Savastano et al.<sup>[137]</sup> identified a reduced perfusion density of the radial peripapillary capillary plexus in COVID-19 patients in comparison to age-based controls. In the OCTA study conducted by Abrishami et al.<sup>[138]</sup> on COVID-19 patients, a decrease in blood flow in superficial and deep capillary plexus was reported.

COVID-19 has been associated with an increased incidence of systemic diseases such as Diabetes Mellitus and Kawasaki disease, which are particularly relevant to ophthalmologists due to potentially severe ocular symptoms.<sup>[139,140]</sup> Due to risk factors such as intensive care unit patients, invasive mechanical ventilation, prone position, and exposure to resistant bacteria, covid patients may experience ocular surface disorders and secondary infections.<sup>[141]</sup> The use of hydroxychloroquine and chloroquine has raised concerns due to their retinal toxic effects. With that said, the risk of retinal toxicity from short-term use of high dose antimalarial is still unknown. Ocular side effects have also been reported with other investigational drugs such as lopinavir-ritonavir, interferons, interleukin-1, and interleukin-6 inhibitors.<sup>[142]</sup>

To conclude, the possible ocular complications and effects of SARS CoV-2 are uncertain, and more comprehensive large case series studies are required to understand further details.

## Otorhinolaryngology and COVID-19

It is a known fact that coronaviruses have neurotrophic and neuroinvasive features. We encounter smell and taste disorders, dizziness, tinnitus, and hearing loss in otorhinolaryngology due to these qualities. Smell disorder, which has been shown to affect the life quality and cause an increase in the incidence of depression, has been detected in 30-70% of SARS COV-2 positive patients.<sup>[143–147]</sup> While the less frequent but prolonged smell and taste dysfunction were seen in SARS disease in 2004-2005, the majority of COVID-19 patients' (%90>) smell and taste dysfunction are improved in 2 weeks after the onset of dysfunctions.<sup>[148,149]</sup> A study showed that 98% of the patients with the complaint of smell disorder resolved within 28 days, and no signs of permanent smell and taste disorders were found.<sup>[150]</sup> The presence of smell disorder symptom, which is more common among hospitalized patients, especially in women and young patients, is an indicator of a good prognosis for the disease.<sup>[150,151]</sup>

It has been shown in previous studies that viral infections have an important role in the etiology of sudden sensorineural hearing loss.<sup>[152]</sup> The initial article that mentions sensorineural hearing loss in SARS CoV-2 was published by Sriwijitalai. A patient with an improved clinical condition



resulting from treatment is presented, yet no signs of improvement in the hearing loss were indicated.<sup>[153]</sup> Rhman et al.<sup>[154]</sup> achieved a partial recovery with intratympanic steroid in an asymptomatic COVID-19 patient with sensorineural hearing loss. During a study performed in Turkey, five patients with a symptom of sudden hearing loss have undertaken PCR tests, and one patient is diagnosed with SARS-CoV-2.<sup>[155]</sup> In another study, when pure tone audiometry and transient evoked otoacoustic emission (TEOAE) results of 20 asymptomatic CoV-PCR positive patients were compared with the control group; higher hearing thresholds and lower TEOAE amplitudes were detected at higher frequencies in COVID-19 patients.<sup>[156]</sup> In the case presented by Degen, he detected a bilateral sensorineural hearing loss in a COVID-19 patient treated in the intensive care unit, and he provided hearing rehabilitation with a cochlear implant in the patient who could not recover with intratympanic steroid therapy.<sup>[157]</sup>

Koumpa et al.<sup>[158]</sup> used oral and intratympanic steroids to tackle sensorineural hearing loss in a COVID-19 patient, yet they could not achieve a noteworthy hearing gain. On the other hand, Cui C. et al.,<sup>[159]</sup> presented a case of a patient with dizziness and instability. They reported that they added betahistine to their treatment to resolve dizziness in this patient who has been previously treated for respiratory system symptoms. Garcia-Romo et al.<sup>[160]</sup> presented young male patients who applied due to dizziness that started one week after the onset of Covid symptoms and horizontal nystagmus accompanied by intermittent rotator component. Chirakkal et al.<sup>[161]</sup> reported a case of a young female patient who applied with tinnitus and had completed the COVID-19 treatment and revealed that COVID-19 infection has harmful effects on the outer hair cells in the cochlea.

What is more important than all these ailments and can lead to mortality is that patients with head and neck cancer cannot reach diagnosis and treatment due to COVID-19. In head and neck cancers, as the time between diagnosis and treatment prolongs, chances of disease-free survival decreases. For this reason, in head and neck surgeries, the period between the patient's application to the clinic and her/his treatment should not exceed one month.<sup>[162]</sup> Despite all the efforts of otorhinolaryngologists, it will be challenging to understand whether this condition is fulfilled during this pandemic process, where almost all hospitals work above their capacities, and doctors work outside their field of expertise, and patients cannot apply to the relevant complaint departments.

## Urology and COVID-19

It is known that male genital organs are affected by viral infections such as mumps, hepatitis, zika, and human im-

munodeficiency virus (HIV). Various complications disrupting the blood-testis barrier (BTB) have been reported in the viremic period.<sup>[163–165]</sup> Disruption of the BTB results in the development of autoimmune disorders, leading to defective spermatogenesis and infertility.<sup>[166]</sup> It has been shown that ACE2 is highly expressed in seminiferous tubule cells, spermatogonia, and Leydig and Sertoli cells of the testis by single-cell RNA sequence analysis.<sup>[167]</sup> SARS-CoV-2 infection can affect several mechanisms of male genital organs.

1. The virus binds directly to the ACE2 receptor, causing epididymo-orchitis and impairing testicular function.
2. Similar to other viral orchitis, SARS-CoV-2 can pass through the BTB, causing autoimmune orchitis with immune response.<sup>[168]</sup>
3. High fever entailed by the disease may cause apoptosis of meiotic germ cells by raising the temperature of the testicles.<sup>[169]</sup>
4. In addition, segmental vascularization in the testicles of COVID-19 patients associated with coagulation abnormality may be responsible for the orchitis-like picture.<sup>[170]</sup>

Li et al.<sup>[171]</sup> detected SARS-CoV-2 positivity by RT-PCR in semen samples of 6 of 38 COVID-19 patients in the acute and early recovery stages of the disease. In a separate study, none of the 34 patients that recovered from the disease in one month after the diagnosis of COVID-19 had SARS CoV-2 in their semen, yet six patients had a scrotal condition supporting viral orchitis in the acute phase.<sup>[172]</sup> Furthermore, in the research conducted by Holtmann et al.,<sup>[173]</sup> SARS-CoV-2 RNA was not detected in semen of healed and acute Covid 19 (+) men. However, they observed that semen parameters were impaired in patients with moderate infection, while they concluded that it was not possible to affect testicular and epididymis function in mild infection. On the other hand, in the autopsy of 6 men who died from SARS infection, symptoms of orchitis such as widespread germ cell destruction with little or no sperm in the seminiferous tubules, thickened testicular basement membrane and lymphocyte infiltration in the interstitial tissue, peritubular fibrosis, and vascular congestion were detected.<sup>[174]</sup> Similar findings such as severe seminiferous tubular damage, reduced Leydig cells, and mild lymphocytic inflammation were also observed in postmortem examinations of men with COVID-19.<sup>[175]</sup>

The effects of COVID-19 on male genital organs and fertility are controversial; there is a need for methodologically well-planned controlled studies in which a sufficient number of patients are evaluated, semen samples are examined in different stages of the disease, and hormonal functions are analyzed.

## Dermatology and COVID-19

Skin lesions can be observed in COVID-19 disease.<sup>[176]</sup> The estimated prevalence of skin findings in COVID-19 is 5.69%. Symptoms include viral exanthema-like rash, maculopapular rash, vesiculobullous lesions, urticarial lesions, chilblain-pernio-like lesions, livedo reticularis, finger-toe gangrene.<sup>[177]</sup> Vesicular rashes may indicate the early diagnosis of COVID-19, acral lesions can be used epidemiologically, vasculitis-like rashes can be used as prognostic factors.<sup>[178]</sup>

Apart from the symptoms observed in the course of the disease, side effects of drugs given during the treatment can be seen on the skin.

The use of hydroxychloroquine in COVID-19 patients may cause induction, deterioration, or relapse of psoriasis.<sup>[179]</sup> Discontinuation of immuno-suppressive therapy in psoriasis patients diagnosed with COVID-19 can also cause exacerbation of psoriasis.<sup>[180]</sup> This situation causes increases in morbidity. Systemic drugs such as methotrexate, cyclosporine, anti-TNF, and other biological smart drugs used in severe cases in psoriasis patients may have to be discontinued due to COVID-19 infection.<sup>[181]</sup> The cessation of treatment may cause very severe psoriasis attacks and joint involvement after COVID-19 infection.

Nonmelanoma skin cancers are the most common cancer among humans, and the primary tumor's surgical excision is the best treatment. Malignant melanoma is a more aggressive variant of cancer, and surgical excision is important before metastasis develops. Delay in diagnosis leads to a missed treatment opportunity.<sup>[181]</sup> The intensity experienced due to COVID-19 makes it difficult for patients to reach a specialist, and the diagnosis is delayed in patients who do not apply to the hospital with the concern of infection.

These conditions may cause an increase in morbidity and mortality in patients. Additional dermatological lesions may be seen after COVID-19 infection, and additional treatment is required for patients. Acral ischemia and gangrene may emerge in patients that are under scrutiny in COVID-19 intensive care units.<sup>[181]</sup> This situation may cause post-Covid permanent limb loss. In some of the post-Covid patients, pre-existing atopic dermatitis, psoriasis, and rosacea illnesses have aggravated.<sup>[181,182]</sup> Therefore, an increase in dermatological morbidity and mortality can be seen due to COVID-19 infection. COVID-19 patients with existing skin illness should be followed carefully.

## Gynecology and COVID-19

ACE-2 mRNA transcripts were detected in ovaries, especially in women of reproductive age and the menopausal period. It was found that ACE-2 receptors are high in ovaries. Hence, ovaries and oocytes could be the potential target of

Covid-19.<sup>[183,184]</sup> ACE-2 induces steroid synthesis and facilitates follicle development, contributes to oocyte maturation and follicular atresia, affects ovulation, and maintains the continuity of the corpus luteum.<sup>[185]</sup> In females, a severe acute illness may alter the hypothalamic-pituitary-gonadal (HPG) axis function, and reduce the endogenous production of Estrogen and Progesterone. Until now, there are no published studies available examining the effect of COVID-19 on female patients' hormone levels. To investigate the effect mentioned, there is a necessity for the examination of long-term data of infected women, as well as additional studies must be conducted.

Covid 19 may also have a negative effect on reproduction by affecting the thyroid function and causing cycle irregularities in the acute and chronic periods on ovulation and reproductive system.<sup>[186]</sup>

According to Genecards data, ACE 2 was also detected in the breast tissue. Covid test was found positive in the breast milk of all 3 Covid-positive mothers. These findings show us that transmission of the virus is possible through breast-feeding<sup>[187]</sup> and the transmission of the virus is within the bounds of possibility through breastfeeding. Covid-19 also raises infection risks in pregnant women and fetuses, premature birth, fetal distress, premature rupture of membranes, and cesarean. Considering that the virus affects the ACE-2 receptors in pregnant women with COVID-19 disease, it is considered that preeclampsia eclampsia, intrauterine growth restriction, and fetal distress may develop in pregnant women. When it is taken into account that vasculitis is one of the long-term complications, it is also assumed that recurrent pregnancy loss, development of intrauterine growth restriction, pregestational or gestational hypertension may also occur in later pregnancies.

## Epigenetics and COVID-19

Epigenetic modifications (e.g., histone acetylation, DNA / RNA methylation, non-coding RNAs mediated regulation) that responsible for the regulation of gene expression play an important role in elucidating the existential threat engendered by the SARS CoV-2 pandemic and its major complications in humans.<sup>[188]</sup> The patient's age, gender, current health status, as well as genomic and epigenomic data are effective on the severity of the Covid 19 disease, the course of the disease, and the long-term sequelae that emerge after the disease.<sup>[189,190]</sup> As discussed many times in the article, differences in DNA methylation motifs on the ACE-2 gene, which is the receptor of SARS-CoV-2, and post-translational changes in histone proteins are associated with the development of different pathophysiological processes in each SARS CoV-2 patient.<sup>[191,192]</sup>

Although there is not much data on the long-term effects of Covid 19, the symptoms that occur after the healing process are not directly caused by the virus, but are a reflection of the inflammatory response and coagulopathies of the body to heal during the disease process. In cases of COVID-19 induced coagulopathies, uncontrolled NET (neutrophil extracellular trap) formation causes respiratory failure, thrombosis, sepsis, acute cardiac injuries, and heart failure.<sup>[193]</sup> NET irregularity is considered to engender symptoms after the disease. In many diseases, imbalances have also been reported in the genetic and epigenetic factors that govern NETosis that neutralize pathogen infestation.<sup>[193,194]</sup> Post-translational modifications, including histone citrullination and histone deacetylation in neutrophils, have been reported to affect neutrophil apoptosis.<sup>[195,196]</sup> With regards to understanding the pathologies that develop after Covid 19 mediated by NETs, it may be important to comprehend the molecular mechanism of NETosis associated with the disease. Defining the epigenetic regulation after Covid 19 infection will shed light on the complexity caused by the disease.

### Global Burden and Future Prospects

The COVID-19 pandemic dominates the global agenda, and given its abruptness, it has deeply affected the health, economy, and education infrastructures of countries. In this study, our foremost ambition was to draw attention to the significant increase in morbidity after COVID-19 disease. Vaccination studies are ongoing to end the epidemic, and approved vaccines are put into practice. With that said, the vaccines developed for COVID-19 will have a considerable cost to countries. Moreover, the exact duration of immunity ensured by these vaccines is currently ambiguous. Hence, even if all societies are vaccinated, there might be a necessity for re-vaccination in the future. It should be anticipated that the additional costs based on this assumption would create an excessive burden on the economies of low and middle-income countries, thus causing problems in the accession to the vaccine of citizens of these countries.

COVID-19 is not a simple upper respiratory tract infection. As stated in our study, COVID-19 is a multisystemic disease that affects many organs and systems, especially the respiratory and circulatory systems, and can leave permanent sequelae in these organs and systems. In patients discharged from the hospital after COVID-19 treatment, problems that require rehabilitation such as breathing problems, weakness, speech, swallowing, nutrition disorders, post-traumatic stress disorder, and memory problems are still being observed.<sup>[197]</sup>

It is obvious that these problems will create a serious burden on individuals and the health systems. This burden

will be felt even heavier by disadvantaged individuals, especially those with low income, the elderly, the disabled, who do not have health insurance and have limited access to the health system.<sup>[198]</sup> Moreover, it is recognized that the COVID-19 pandemic has negative social and negative consequences in all countries. Within the pandemic context, different measures implemented such as curfews, travel bans, closure of various shops (e.g., bars, restaurants, cinemas), and restrictions on tourism activities almost completely halted economic activities.<sup>[199]</sup> It is vital to conduct comprehensive planning to prevent problems that may develop after COVID-19 and manage public health consequences.

### Disclosures

**Acknowledgement:** We thank Hasan Lütfi Baycol for helping with Figures.

**Ethics Committee Approval:** Ethics committee approval was not requested for this study.

**Peer-review:** Externally peer-reviewed.

**Conflict of Interest:** None declared.

**Authorship Contributions:** Concept – A.R.S.; Design – A.R.S., H.E.S.; Supervision – A.R.S., H.E.S., M.E.S., S.A.; Materials – A.R.S., M.E.S., B.F.K.; Data collection &/or processing – A.R.S., M.E.S., B.F.K.; Analysis and/or interpretation – A.R.S., M.E.S., B.F.K.; Literature search – A.M.T.; Writing – A.R.S., B.F.K., E.A., B.A., M.S., M.E.S., H.E.S., E.G., M.B., D.T., H.S., R.A.O., A.E., L.O., A.A., C.T., I.C., D.C., S.U., M.K.D., O.M., A.T., A.B., R.D., A.M., S.A.; Critical review – A.R.S., B.F.K., E.A., B.A., M.S., M.E.S., H.E.S., E.G., M.B., D.T., H.S., R.A.O., A.E., L.O., A.A., C.T., I.C., D.C., S.U., M.K.D., O.M., A.T., A.B., R.D., A.M., S.A.

### References

1. Zhu N, Zhang D, Wang W, Li X, Yang B, Song J et al; China Novel Coronavirus Investigating and Research Team. A Novel Coronavirus from Patients with Pneumonia in China, 2019. *N Engl J Med* 2020;382:727–33. [\[CrossRef\]](#)
2. Onder G, Rezza G, Brusaferro S. Case-Fatality Rate and Characteristics of Patients Dying in Relation to COVID-19 in Italy. *JAMA* 2020;323:1775–6. [\[CrossRef\]](#)
3. Kumar A, Gupta PK, Srivastava A. A review of modern technologies for tackling COVID-19 pandemic. *Diabetes Metab Syndr* 2020;14:569–73. [\[CrossRef\]](#)
4. Tang YW, Schmitz JE, Persing DH, Stratton CW. Laboratory Diagnosis of COVID-19: Current Issues and Challenges. *J Clin Microbiol* 2020;58:e00512–20. [\[CrossRef\]](#)
5. Ihle-Hansen H, Berge T, Tveita A, Rønning EJ, Ernø PE, Andersen EL, et al. COVID-19: Symptoms, course of illness and use of clinical scoring systems for the first 42 patients admitted to a Norwegian local hospital. *Tidsskr Nor Lægeforen* 2020;140.
6. Centers for Disease Control and Prevention, National Center for Immunization and Respiratory Diseases (NCIRD) Division



- of Viral Diseases. Symptoms of Coronavirus. Available at: <https://www.cdc.gov/coronavirus/2019-ncov/symptoms-testing/symptoms.html>. Accessed Dec 28, 2020.
7. Wordlometers, Coronavirus. Available at: <https://www.worldometers.info/coronavirus/>. Accessed Dec 28, 2020.
  8. Ye Q, Wang B, Mao J. The pathogenesis and treatment of the 'Cytokine Storm' in COVID-19. *J Infect* 2020;80:607–13. [\[CrossRef\]](#)
  9. Li G, He X, Zhang L, Ran Q, Wang J, Xiong A, et al. Assessing ACE2 expression patterns in lung tissues in the pathogenesis of COVID-19. *J Autoimmun* 2020;112:102463. [\[CrossRef\]](#)
  10. WHO. 2019- nCoV Situation Report-1 on 21 January, 2020. Available at: <https://www.who.int/emergencies/diseases/novel-coronavirus-2019/situation-reports/>. Accessed Jan 21, 2020.
  11. Hui DS, Wong KT, Ko FW, Tam LS, Chan DP, Woo J, et al. The 1-year impact of severe acute respiratory syndrome on pulmonary function, exercise capacity, and quality of life in a cohort of survivors. *Chest* 2005;128:2247–61. [\[CrossRef\]](#)
  12. Hui DS, Joynt GM, Wong KT, Gomersall CD, Li TS, Antonio G, et al. Impact of severe acute respiratory syndrome (SARS) on pulmonary function, functional capacity and quality of life in a cohort of survivors. *Thorax* 2005;60:401–9. [\[CrossRef\]](#)
  13. Antonio GE, Wong KT, Hui DS, Wu A, Lee N, Yuen EH, et al. Thin-section CT in patients with severe acute respiratory syndrome following hospital discharge: preliminary experience. *Radiology* 2003;228:810–5. [\[CrossRef\]](#)
  14. Das KM, Lee EY, Singh R, Enani MA, Al Dossari K, Van Gorkom K, et al. Follow-up chest radiographic findings in patients with MERS-CoV after recovery. *Indian J Radiol Imaging* 2017;27:342–9. [\[CrossRef\]](#)
  15. Gentile F, Aimo A, Forfori F, Catapano G, Clemente A, Cademartiri F, et al. COVID-19 and risk of pulmonary fibrosis: the importance of planning ahead. *Eur J Prev Cardiol* 2020;27:1442–6.
  16. Zhang H, Zhou P, Wei Y, Yue H, Wang Y, Hu M, et al. Histopathologic Changes and SARS-CoV-2 Immunostaining in the Lung of a Patient With COVID-19. *Ann Intern Med* 2020;172:629–32.
  17. Wang Y, Dong C, Hu Y, Li C, Ren Q, Zhang X, et al. Temporal Changes of CT Findings in 90 Patients with COVID-19 Pneumonia: A Longitudinal Study. *Radiology* 2020;296:E55–E64.
  18. Zhao YM, Shang YM, Song WB, Li QQ, Xie H, Xu QF, et al. Follow-up study of the pulmonary function and related physiological characteristics of COVID-19 survivors three months after recovery. *EclinicalMedicine* 2020;25:100463. [\[CrossRef\]](#)
  19. Klok FA, Kruip MJHA, van der Meer NJM, Arbous MS, Gommers DAMPJ, Kant KM, et al. Incidence of thrombotic complications in critically ill ICU patients with COVID-19. *Thromb Res* 2020;191:145–7. [\[CrossRef\]](#)
  20. Wichmann D, Sperhake JP, Lütgehetmann M, Steurer S, Edler C, Heinemann A, et al. Autopsy Findings and Venous Thromboembolism in Patients With COVID-19: A Prospective Cohort Study. *Ann Intern Med* 2020;173:268–77. [\[CrossRef\]](#)
  21. Wang HJ, Ding YQ, Xu J, Li X, Li XF, Yang L, et al. Death of a SARS case from secondary aspergillus infection. *Chin Med J (Engl)* 2004;117:1278–80.
  22. Hwang DM, Chamberlain DW, Poutanen SM, Low DE, Asa SL, Butany J. Pulmonary pathology of severe acute respiratory syndrome in Toronto. *Mod Pathol* 2005;18:1–10. [\[CrossRef\]](#)
  23. Nishiga M, Wang DW, Han Y, Lewis DB, Wu JC. COVID-19 and cardiovascular disease: from basic mechanisms to clinical perspectives. *Nat Rev Cardiol* 2020;17:543–58. [\[CrossRef\]](#)
  24. Faconti L, Chowieniczky PJ and Shah AM. Cardiovascular disease, heart failure and COVID-19. *J Renin Angiotensin Aldosterone Syst* 2020;21:1470320320926903. [\[CrossRef\]](#)
  25. Rivera-Morales MD, Pell R, Rubero J, Ganti L. Acute Myopericarditis in the Post COVID-19 Recovery Phase. *Cureus* 2020;12(e11247). [\[CrossRef\]](#)
  26. Konar N, Saha P, Moseley A, Denman J, Hatahintwali F, Ali R, et al. Cardiovascular Manifestations in COVID-19: Analysis of a Case Series of Hospital Admissions with Laboratory Confirmed SARS-CoV-2 PCR tests. *The Physician* 2020;6:1–7. [\[CrossRef\]](#)
  27. Puntmann VO, Carerj ML, Wieters I, Fahim M, Arendt C, Hoffmann J, et al. Outcomes of Cardiovascular Magnetic Resonance Imaging in Patients Recently Recovered From Coronavirus Disease 2019 (COVID-19). *JAMA Cardiol* 2020;5:1265–73.
  28. Rajpal S, Tong MS, Borchers J, Zareba KM, Obarski TP, Simonetti OP, et al. Cardiovascular Magnetic Resonance Findings in Competitive Athletes Recovering From COVID-19 Infection. *JAMA Cardiol* 2021;6:116–8. [\[CrossRef\]](#)
  29. Yang C, Jin Z. An Acute Respiratory Infection Runs Into the Most Common Noncommunicable Epidemic-COVID-19 and Cardiovascular Diseases. *JAMA Cardiol* 2020;5:743–4. [\[CrossRef\]](#)
  30. Mehta JL, Calcaterra G, Bassareo PP. COVID-19, thromboembolic risk, and Virchow's triad: Lesson from the past. *Clin Cardiol* 2020;43:1362–7. [\[CrossRef\]](#)
  31. Varga Z, Flammer AJ, Steiger P, Haberecker M, Andermatt R, Zinkernagel AS, et al. Endothelial cell infection and endothelitis in COVID-19. *Lancet* 2020;395:1417–8. [\[CrossRef\]](#)
  32. Korupolu R, Francisco GE, Levin H, Needham DM. Rehabilitation of critically ill COVID-19 survivors. *J Int Soc Phys Rehabil Med* 2020;3:45–52. [\[CrossRef\]](#)
  33. Gutenbrunner C, Stokes EK, Dreinhofer K, Monsbakken J, Clarke S, Côté P, et al. Why Rehabilitation must have priority during and after the COVID-19-pandemic: A position statement of the Global Rehabilitation Alliance. *J Rehabil Med* 2020;52:jrm00081. [\[CrossRef\]](#)
  34. Hsieh MJ, Lee WC, Cho HY, Wu MF, Hu HC, Kao KC, et al. Recovery of pulmonary functions, exercise capacity, and quality of life after pulmonary rehabilitation in survivors of ARDS due to severe influenza A (H1N1) pneumonitis. *Influenza Other Respir Viruses* 2018;12:643–8. [\[CrossRef\]](#)
  35. Kiekens C, Boldrini P, Andreoli A, Avesani R, Gamna F, Grandi M, et al. Rehabilitation and respiratory management in the

- acute and early post-acute phase. "Instant paper from the field" on rehabilitation answers to the COVID-19 emergency. *Eur J Phys Rehabil Med* 2020;56:323–6. [\[CrossRef\]](#)
36. Simpson R, Robinson L. Rehabilitation After Critical Illness in People With COVID-19 Infection. *Am J Phys Med Rehabil* 2020;99:470–4. [\[CrossRef\]](#)
  37. Mao L, Jin H, Wang M, Hu Y, Chen S, He Q, et al. Neurologic Manifestations of Hospitalized Patients With Coronavirus Disease 2019 in Wuhan, China. *JAMA Neurol* 2020;77:683–90.
  38. Steardo L, Steardo L Jr, Zorec R, Verkhatsky A. Neuroinfection may contribute to pathophysiology and clinical manifestations of COVID-19. *Acta Physiol (Oxf)* 2020;229:13473. [\[CrossRef\]](#)
  39. Han R, Huang L, Jiang H, Dong J, Peng H, Zhang D. Early Clinical and CT Manifestations of Coronavirus Disease 2019 (COVID-19) Pneumonia. *AJR Am J Roentgenol* 2020:338–43. [\[CrossRef\]](#)
  40. Jajodia A, Ebner L, Heidinger B, Chaturvedi A, Prosch H. Imaging in corona virus disease 2019 (COVID-19)-A Scoping review. *Eur J Radiol Open*. 2020;7:100237. [\[CrossRef\]](#)
  41. Liu D, Zhang W, Pan F, Li L, Yang L, Zheng D, et al. The pulmonary sequelae in discharged patients with COVID-19: a short-term observational study. *Respir Res* 2020;21:125. [\[CrossRef\]](#)
  42. Wu X, Dong D, Ma D. Thin-section computed tomography manifestations during convalescence and long-term follow-up of patients with severe acute respiratory syndrome (SARS). *Med Sci Monit* 2016;22:2793–9. [\[CrossRef\]](#)
  43. Huang C, Wang Y, Li X, Ren L, Zhao J, Hu Y, et al. Clinical features of patients infected with 2019 novel coronavirus in Wuhan, China. *Lancet* 2020;395:497–506. [\[CrossRef\]](#)
  44. Öztürk Ş. COVID-19 and Neurology. *Turk J Neurol* 2020;26:109–11. [\[CrossRef\]](#)
  45. Heneka MT, Golenbock D, Latz E, Morgan D, Brown R. Immediate and long-term consequences of COVID-19 infections for the development of neurological disease. *Alzheimer's research & therapy* 2020;12:69. [\[CrossRef\]](#)
  46. Yu H, Sun T, Feng J. Complications and Pathophysiology of COVID-19 in the Nervous System *Front Neurol* 2020;11:573421.
  47. Giacomelli A, Pezzati L, Conti F, Bernacchia D, Siano M, Oreni L, et al. Self-reported Olfactory and Taste Disorders in Patients With Severe Acute Respiratory Coronavirus 2 Infection: A Cross-sectional Study. *Clinical infectious diseases: an official publication of the Infectious Diseases Society of America* 2020;71:889–90. [\[CrossRef\]](#)
  48. Helms J, Kremer S, Merdji H. Neurologic Features in Severe SARS-CoV-2 Infection 2020;382:2268–70. [\[CrossRef\]](#)
  49. Tejera D, Mercan D, Sanchez-Caro JM, Hanan M, Greenberg D, Soreq H. Systemic inflammation impairs microglial A $\beta$  clearance through NLRP3 inflammasome. *EMBO J* 2019;38:e101064.
  50. Fotuhi M, Mian A, Meysami S, Raji CA. Neurobiology of COVID-19. *J Alzheimers Dis* 2020;76:3–19. [\[CrossRef\]](#)
  51. Wijeratne T, Crewther S. Post-COVID 19 Neurological Syndrome (PCNS); a novel syndrome with challenges for the global neurology community. *Journal of the neurological sciences* 2020;419:117179. [\[CrossRef\]](#)
  52. Berger JR. COVID-19 and the nervous system. *Journal of neurovirology* 2020;26:143–8. [\[CrossRef\]](#)
  53. Taylor S, Landry CA, Paluszczek MM, Fergus TA, McKay D, Asmundson GJ. COVID stress syndrome: Concept, structure, and correlates. *Depress Anxiety* 2020;37:706–14. [\[CrossRef\]](#)
  54. Knowles KA, Olatunji BO. Anxiety and safety behavior usage during the COVID-19 pandemic: The prospective role of contamination fear. *J Anxiety Disord* 2020;77:102323. [\[CrossRef\]](#)
  55. Vindegaard N, Benros ME. COVID-19 pandemic and mental health consequences: Systematic review of the current evidence. *Brain Behav Immun* 2020;89:531–42. [\[CrossRef\]](#)
  56. Wang C, Pan R, Wan X, Tan y, Xu L, McIntyre RS, et al. A longitudinal study on the mental health of general population during the COVID-19 epidemic in China. *Brain Behav Immun* 2020;87:40–8. [\[CrossRef\]](#)
  57. Pandey D, Bansal S, Goyal S, Garg A, Sethi N, Pothiyill DI, et al. Psychological impact of mass quarantine on population during pandemics-The COVID-19 Lock-Down (COLD) study. *PLoS One* 2020;15:e0240501. [\[CrossRef\]](#)
  58. Lawson M, Piel MH, Simon M. Child Maltreatment during the COVID-19 Pandemic: Consequences of Parental Job Loss on Psychological and Physical Abuse Towards Children. *Child Abuse Negl* 2020;110:104709. [\[CrossRef\]](#)
  59. Tang F, Liang J, Zhang H, Kelifa MM, He Q, Wang P. COVID-19 related depression and anxiety among quarantined respondents. *Psychol Health* 2020;36:164–78. [\[CrossRef\]](#)
  60. Taquet M, Luciano S, Geddes JR, Harriossn PJ. Bidirectional associations between COVID-19 and psychiatric disorder: retrospective cohort studies of 62 354 COVID-19 cases in the USA. *Lancet* 2021;8:130–40. [\[CrossRef\]](#)
  61. Tomasoni D, Bai F, Castoldi R, Barbanotti D, Falcinella C, Mulè G, et al. Anxiety and depression symptoms after virological clearance of COVID-19: A cross-sectional study in Milan, Italy. *J Med Virol* 2021;93:1175–9. [\[CrossRef\]](#)
  62. Mazza MG, De Lorenzo R, Conte C, Poletti S, Vai B, Bollettini I, et al. Anxiety and depression in COVID-19 survivors: Role of inflammatory and clinical predictors. *Brain Behav Immun* 2020;89:594–600. [\[CrossRef\]](#)
  63. Chang MC, Park D. Incidence of Post-Traumatic Stress Disorder After Coronavirus Disease. *Healthcare (Basel)* 2020;8:373.
  64. Horn M, Wathélet M, Fovet T, Amad A, Vuotto F, Faure K, et al. Is COVID-19 Associated With Posttraumatic Stress Disorder? The Journal of clinical psychiatry 2020;82:20m13641. [\[CrossRef\]](#)
  65. Poyraz BC, Poyraz CA, Olgun Y, Gurel O, Alkan S, Ozdemir YE, et al. Psychiatric morbidity and protracted symptoms after COVID-19. *Psychiatry Res* 2020;295:113604. [\[CrossRef\]](#)
  66. Li LZ, Wang S. Prevalence and predictors of general psychiatric disorders and loneliness during COVID-19 in the United Kingdom. *Psychiatry Res* 2020;291:113267. [\[CrossRef\]](#)

67. Killgore WD, Cloonen SA, Taylor EC, Dailey NS. Loneliness: A signature mental health concern in the era of COVID-19. *Psychiatry Research* 2020;290:113117. [\[CrossRef\]](#)
68. Hampshire A, Trender W, Chamberlain S, Grant AJJE, Patrick F, Mazibuko N, et al. Cognitive Cognitive deficits in people who have recovered from COVID-19 relative to controls: An N= 84,285 online study. medRxiv. 2020 Oct 21. Doi: <https://doi.org/10.1101/2020.10.20.20215863>. [Epub ahead of print]. [\[CrossRef\]](#)
69. Rogers JP, Chesney E, Oliver D, Pollak TA, McGuire PP, Fusar-Poli P, et al. Psychiatric and neuropsychiatric presentations associated with severe coronavirus infections: a systematic review and meta-analysis with comparison to the COVID-19 pandemic. *The Lancet Psychiatry* 2020;7:611–27. [\[CrossRef\]](#)
70. Jaworowski S, Weiser M, Gropp C, Malka M. Three Cases of COVID-19-related First Onset Brief Reactive Psychosis. *Isr Med Assoc J* 2020;22:612.
71. Huarcaya-Victoria J, Meneses-Saco A, Luna-Cuadros MA. Psychotic symptoms in COVID-19 infection: A case series from Lima, Peru. *Psychiatry Res* 2020;293:113378. [\[CrossRef\]](#)
72. Caan MP, Lim CT, Howard M. A Case of Catatonia in a Man With COVID-19. *Psychosomatics* 2020;61:556–60. [\[CrossRef\]](#)
73. Zou R, Wu C, Zhang S, Wang G, Zhang Q, Yu B, et al. Euthyroid Sick Syndrome in Patients With COVID-19. *Front Endocrinol (Lausanne)* 2020;11:566439. [\[CrossRef\]](#)
74. Asfuroglu Kalkan E, Ates I. A case of subacute thyroiditis associated with COVID-19 infection. *J Endocrinol Invest* 2020;43:1173–4. [\[CrossRef\]](#)
75. Mattar SAM, Koh SJQ, Rama Chandran S, Cherng BPZ. Subacute thyroiditis associated with COVID-19. *BMJ Case Rep* 2020;13:3–6. [\[CrossRef\]](#)
76. Campos-Barrera E, Alvarez-Cisneros T, Davalos-Fuentes M. Subacute Thyroiditis Associated with COVID-19. *Case Rep Endocrinol* 2020;2020:7–10. [\[CrossRef\]](#)
77. Pastor S, Molina Á, De Celis E. Thyrotoxic Crisis and COVID-19 Infection: An Extraordinary Case and Literature Review. *Cureus* 2020;12:1–8. [\[CrossRef\]](#)
78. Mateu-Salat M, Urgell E, Chico A. SARS-COV-2 as a trigger for autoimmune disease: report of two cases of Graves' disease after COVID-19. *J Endocrinol Invest* 2020;43:1527–8. [\[CrossRef\]](#)
79. Rotondi M, Coperchini F, Ricci G, Denegri M, Croce L, Ngnitejeu ST, et al. Detection of SARS-COV-2 receptor ACE-2 mRNA in thyroid cells: a clue for COVID-19-related subacute thyroiditis. *J Endocrinol Invest* 2020:1–6. [\[CrossRef\]](#)
80. Mizuno S, Inaba H, Kobayashi KI, Kubo K, Ito S, Hirobata T, et al. A case of postpartum thyroiditis following SARS-CoV-2 infection. *Endocr J*. 2020 Nov 12. doi: 10.1507/endocrj.EJ20–0553. [Epub ahead of print]. [\[CrossRef\]](#)
81. Kumar A, Arora A, Sharma P, Anikhindi SA, Bansal N, Singla V, et al. Is diabetes mellitus associated with mortality and severity of COVID-19? A meta-analysis. *Diabetes Metab Syndr* 2020;14:535–45. [\[CrossRef\]](#)
82. Palermo NE, Sadhu AR, McDonnell ME. Diabetic Ketoacidosis in COVID-19: Unique Concerns and Considerations. *J Clin Endocrinol Metab* 2020;105: dgaa360. [\[CrossRef\]](#)
83. Chan KH, Thimmarreddygari D, Ramahi A, Atallah L, Baranetsky NG, Slim J. Clinical characteristics and outcome in patients with combined diabetic ketoacidosis and hyperosmolar hyperglycemic state associated with COVID-19: A retrospective, hospital-based observational case series. *Diabetes Res Clin Pract* 2020;166:108279. [\[CrossRef\]](#)
84. Rubino F, Amiel SA, Zimmet P, Alberti G, Bornstein S, Eckel RH, et al. New-Onset Diabetes in Covid-19. *N Engl J Med* 2020;383:789–90. [\[CrossRef\]](#)
85. Hollstein T, Schulte DM, Schulz J, Glück A, Ziegler AG, Bonifacio E, et al. Autoantibody-negative insulin-dependent diabetes mellitus after SARS-CoV-2 infection: a case report. *Nat Metab* 2020;2:1021–4. [\[CrossRef\]](#)
86. Santana MF, Borba MGS, Baía-Da-Silva DC, Val F, Alexandre MAA, Brito-Sousa JD, et al. Case report: Adrenal pathology findings in severe COVID-19: An autopsy study. *Am J Trop Med Hyg* 2020;103:1604–7. [\[CrossRef\]](#)
87. Porras MG. Primary adrenal insufficiency secondary to COVID-19 infection: A case report. *Endocr Abstr*. Sep 5 2020. Doi: 101530/endoabs70AEP1015. [Epub Ahead of print].
88. Frankel M, Feldman I, Levine M, Frank Y, Bogot NR, Benjamini O, et al. Bilateral Adrenal Hemorrhage in Coronavirus Disease 2019 Patient: A Case Report. *J Clin Endocrinol Metab* 2020;105:dgaa487. [\[CrossRef\]](#)
89. Álvarez-Troncoso J, Larrauri MZ, Vega MDM, Vallano RG, Peláez EP, Rojas-Marcos PM, et al. Case Report: COVID-19 with Bilateral Adrenal Hemorrhage. *Am J Trop Med Hyg* 2020;103:1156–7.
90. Sharrack N, Baxter CT, Paddock M, Uchegbu E. Adrenal haemorrhage as a complication of COVID-19 infection. *BMJ Case Rep* 2020;13:e239643. [\[CrossRef\]](#)
91. Kumar R, Guruparan T, Siddiqi S, Sheth R, Jacyna M, Naghibi M, et al. A case of adrenal infarction in a patient with COVID 19 infection. *BJR|case reports* 2020;6:20200075. [\[CrossRef\]](#)
92. Rajevac H, Bachan M, Khan Z. Diabetes Insipidus As A Symptom Of Covid-19 Infection: Case Report *Chest* 2020;158:A2576.
93. Guan W, Ni Z, Hu Y, Liang W, Ou C, He J, et al. Clinical characteristics of coronavirus disease 2019 in China. *N Engl J Med* 2020;382:1708–20. [\[CrossRef\]](#)
94. Unuvar A. COVID-19 and Coagulopathy. *Sağlık Bilimlerinde İleri Araştırmalar Dergisi* 2020;3:S53–S62.
95. Wang T, Chen R, Liu C, Liang W, Guan W, Tang R, et al. Attention should be paid to venous thromboembolism prophylaxis in the management of COVID-19. *Lancet Haematol* 2020;7:362–3.
96. Demelo-Rodríguez P, Cervilla-Muñoz E, Ordieres-Ortega L, Parra-Virto A, Toledano-Macías M, Toledo-Samaniego N, et al. Incidence of asymptomatic deep vein thrombosis in patients with COVID-19 pneumonia and elevated D-dimer levels. *Thromb Res* 2020;192:23–6. [\[CrossRef\]](#)



97. Tang N, Li D, Wang X, Sun Z. Abnormal coagulation parameters are associated with poor prognosis in patients with novel coronavirus pneumonia. *J Thromb Haemost* 2020;18:844–7.
98. Günertem E, Akay T, Aliyev A, Beyazpınar S, Erdil N, Erer D, et al. Treatment and prophylaxis strategies for deep vein thrombosis during COVID-19 outbreak. *Turk J Vasc Surg* 2020;29:203–7.
99. Mei H, Hu Y. Characteristics, causes, diagnosis and treatment of coagulation dysfunction in patients with COVID-19. [Article in Chinese]. *Zhonghua Xue Ye Xue Za Zhi* 2020;41:185–91.
100. Gao QY, Chen YX, Fang JY. 2019 Novel coronavirus infection and gastrointestinal tract. *J Dig Dis* 2020;21:125–6. [CrossRef]
101. Yang RX, Zheng RD, Fan JG. Etiology and management of liver injury in patients with COVID-19. *World J Gastroenterol* 2020;26:4753–62. [CrossRef]
102. Wang D, Hu B, Hu C, Zhu F, Liu X, Zhang J, et al. Clinical characteristics of 138 hospitalized patients with 2019 novel coronavirus-infected pneumonia in Wuhan, China. *JAMA* 2020;323:1061–9. [CrossRef]
103. Huang JF, Zheng KI, George J, Gao HN, Wei RN, Yan HD, et al. Fatal outcome in a liver transplant recipient with COVID-19. *Am J Transplant* 2020;20:1907–10. [CrossRef]
104. Fishman JA, Grossi PA. Novel coronavirus-19 (COVID-19) in the immunocompromised transplant recipient: #flatteningthecurve. *Am J Transplant* 2020;20:1765–7. [CrossRef]
105. Cha MH, Regueiro M, Sandhu DS. Gastrointestinal and hepatic manifestations of COVID-19: A comprehensive review. *World J Gastroenterol* 2020;26:2323–32. [CrossRef]
106. Mao R, Qiu Y, He JS, Tan JY, Li XH, Liang J, et al. Manifestations and prognosis of gastrointestinal and liver involvement in patients with COVID-19: a systematic review and meta-analysis. *Lancet Gastroenterol Hepatol* 2020;5:667–78. [CrossRef]
107. Chen N, Zhou M, Dong X, Qu J, Gong F, Han Y, et al. Epidemiological and clinical characteristics of 99 cases of 2019 novel coronavirus pneumonia in Wuhan, China: a descriptive study. *Lancet* 2020;395:507–13. [CrossRef]
108. Joob B, Wiwanitkit V. Novel Middle East respiratory syndrome and renal failure. *Ren Fail* 2014;36:147. [CrossRef]
109. Li Z, Wu M, Guo J, Liao X, Song S, Li J, et al. Caution on Kidney Dysfunctions of COVID-19 Patients. SSRN. 2020 Apr 1. Doi: <https://doi.org/10.2139/ssrn.3559601>. [Epub ahead of print].
110. Cheng Y, Luo R, Wang K, Zhang M, Wang Z, Dong L, et al. Kidney disease is associated with inhospital death of patients with COVID-19. *Kidney Int* 2020;97:829–38. [CrossRef]
111. Ahmed AR, Ebad CA, Stoneman S, Satti MM, Conlon PJ. Kidney injury in COVID19. *World J Nephrol* 2020;9:18–32. [CrossRef]
112. Ronco C, Reis T. Kidney involvement in COVID-19 and rationale for extracorporeal therapies. *Nat Rev Nephrol* 2020;16:308–10. [CrossRef]
113. Diao B, Wang C, Wang R, Feng Z, Tan Y, Wang H, et al. Human kidney is a target for novel severe acute respiratory syndrome coronavirus 2 (SARS-CoV-2) infection. *medRxiv* 2020 Apr 10. Doi: <https://doi.org/10.1101/2020.03.04.20031120>. [Epub ahead of print]. [CrossRef]
114. Kunutsor SK, Laukkanen JA. Renal complications in COVID-19: a systematic review and meta-analysis. *Ann Med* 2020;52:345–53. [CrossRef]
115. Wang W, Gao R, Zheng Y, Jiang L. COVID-19 with spontaneous pneumothorax, pneumomediastinum and subcutaneous emphysema. *J Travel Med* 2020;27:taaa062. [CrossRef]
116. Sun R, Liu H, Wang X. Mediastinal Emphysema, Giant Bulla, and Pneumothorax Developed during the Course of COVID-19 Pneumonia. *Korean J Radiol* 2020;21:541–4. [CrossRef]
117. Salehi S, Abedi A, Balakrishnan S, Gholamrezanezhad A. Coronavirus Disease 2019 (COVID-19): A Systematic Review of Imaging Findings in 919 Patients. *AJR Am J Roentgenol* 2020;215:87–93. [CrossRef]
118. Sahn SA, Heffner JE. Spontaneous pneumothorax. *N Engl J Med* 2000;342:868–74. [CrossRef]
119. McGuinness G, Zhan C, Rosenberg N, Azour L, Wickstrom M, Mason DM, et al. Increased Incidence of Barotrauma in Patients with COVID-19 on Invasive Mechanical Ventilation. *Radiology* 2020;297:252–62. [CrossRef]
120. López Vega JM, Parra Gordo ML, Díez Tascón A, Ossaba Vélez S. Pneumomediastinum and spontaneous pneumothorax as an extrapulmonary complication of COVID-19 disease. *Emerg Radiol* 2020;27:727–30. [CrossRef]
121. Sihoe AD, Wong RH, Lee AT, Lau LS, Leung NY, Law KI, et al. Severe acute respiratory syndrome complicated by spontaneous pneumothorax. *Chest* 2004;125:2345–51. [CrossRef]
122. Das KM, Lee EY, Al Jawder SE, Enani MA, Singh R, Skakni R, et al. Acute Middle East Respiratory Syndrome Coronavirus: Temporal Lung Changes Observed on the Chest Radiographs of 55 Patients. *American Journal of Roentgenology* 2015;205:267–74. [CrossRef]
123. Pieracci FM, Burlew CC, Spain D, Livingston DH, Bulger EM, Davis KA, et al. Tube thoracostomy during the COVID-19 pandemic: guidance and recommendations from the AAST Acute Care Surgery and Critical Care Committees. *Trauma Surg Acute Care Open* 2020;5:e000498. [CrossRef]
124. Schaller T, Hirschebuhl K, Burkhardt K, Braun G, Trepel M, Markl B, et al. Postmortem examination of patients with COVID-19. *JAMA* 2020;323:2518–20. [CrossRef]
125. Akhtar MR, Ricketts W, Fotheringham T. Use of an antiviral filter attached to a pleural drain bottle to prevent aerosol contamination with SARS-CoV-2. *Clin Med* 2020;20:60–1. [CrossRef]
126. Hallifax R, Wrightson JM, Bibby A, Walker S, Stanton A, Fonsaka DD et al. Pleural Services During the COVID-19 Pandemic – Revised. Available at: <https://www.brit-thoracic.org.uk/document-library/quality-improvement/covid-19/pleural-services-during-covid-19-pandemic/>. Accessed May 21, 2020.
127. Seah I, Agrawal R. Can the Coronavirus Disease 2019 (CO-

- VID-19) Affect the Eyes? A Review of Coronaviruses and Ocular Implications in Humans and Animals. *Ocul Immunol Inflamm* 2020;28:391–5. [CrossRef]
128. Wan Y, Shang J, Graham R, Baric RS, Li F. Receptor Recognition by the Novel Coronavirus from Wuhan: an Analysis Based on Decade-Long Structural Studies of SARS Coronavirus. *J Virol* 2020;94:e00127–20. [CrossRef]
  129. Cheema M, Aghazadeh H, Nazarali S, Ting A, Hodges J, McFarlane A, et al. Keratoconjunctivitis as the initial medical presentation of the novel coronavirus disease 2019 (COVID-19). *Can J Ophthalmol* 2020;55:125–9. [CrossRef]
  130. Zhang X, Chen X, Chen L, Deng C, Zou X, Liu W, et al. The evidence of SARS-CoV-2 infection on ocular surface. *Ocul Surf* 2020;18:360–2. [CrossRef]
  131. Wu P, Duan F, Luo C, Liu Q, Qu X, Liang L, et al. Characteristics of Ocular Findings of Patients With Coronavirus Disease 2019 (COVID-19) in Hubei Province, China. *JAMA Ophthalmol* 2020;138:575–8. [CrossRef]
  132. Chen L, Liu M, Zhang Z, Qiao K, Huang T, Chen M, et al. Ocular manifestations of a hospitalised patient with confirmed 2019 novel coronavirus disease. *Br J Ophthalmol* 2020;104:748–51. [CrossRef]
  133. Ocansey S, Abu EK, Abraham CH, Owusu-Ansah A, Boadi-Kusi SB, Illechie AA, Acheampong DO. Ocular Symptoms of SARS-CoV-2: Indication of Possible Ocular Transmission or Viral Shedding. *Ocul Immunol Inflamm* 2020;28:1269–79.
  134. Chin MS, Hooper LC, Hooks J, Detrick B. Identification of  $\alpha$ -fodrin as an autoantigen in experimental coronavirus retinopathy (ECOR). *Journal of Neuroimmunology* 2014;272:42–50. [CrossRef]
  135. Marinho PM, Marcos AAA, Romano AC, Nascimento H, Belfort R Jr. Retinal findings in patients with COVID-19. *Lancet* 2020;395:1610. [CrossRef]
  136. Vavvas DG, Sarraf D, Sadda SR, Elliott D, Ehlers JP, Waheed NK, et al. Concerns about the interpretation of OCT and fundus findings in COVID-19 patients in recent Lancet publication. *Eye (Lond)* 2020;34:2153–4. [CrossRef]
  137. Savastano A, Cricoli E, Savastano MC, Younis S, Gambini G, De Vico U, et al. Peripapillary retinal vascular involvement in early post-COVID-19 patients. *Journal of Clinical Medicine* 2020;9:2895. [CrossRef]
  138. Abrishami M, Emamverdian Z, Shoeibi N, Omidtabrizi A, Daneshvar R, Saeidi Rezvani T, et al. Optical coherence tomography angiography analysis of the retina in patients recovered from COVID-19: a case-control study. *Can J Ophthalmol* 2021;56:24–30. [CrossRef]
  139. Verdoni L, Mazza A, Gervasoni A, Martelli L, Ruggeri M, Ciuffreda M, et al. An outbreak of severe Kawasaki-like disease at the Italian epicentre of the SARS-CoV-2 epidemic: an observational cohort study. *Lancet* 2020;395:1771–8. [CrossRef]
  140. Krogh-Madsen R, Thyfault JP, Broholm C, Mortensen OH, Olsen RH, Mounier R, et al. A 2-wk reduction of ambulatory activity attenuates peripheral insulin sensitivity. *J Appl Physiol* 2010;108:1034–40. [CrossRef]
  141. Saritas TB, Bozkurt B, Simsek B, Cakmak Z, Ozdemir M, Yonsunkaya A. Ocular surface disorders in intensive care unit patients. *Scientific World Journal* 2013;2013:182038. [CrossRef]
  142. Bertoli F, Veritti D, Danese, Samassa F, Sarao V, Rassu N, et al. Ocular Findings in COVID-19 Patients: A Review of Direct Manifestations and Indirect Effects on the Eye. *Journal of Ophthalmology* 2020;2020:4827304. [CrossRef]
  143. American Academy of Otolaryngology–Head and Neck Surgery. Anosmia, Hyposmia, and Dysgeusia Symptoms of Coronavirus Disease. Available at: <https://www.entnet.org/content/aao-hns-anosmia-hyposmia-and-dysgeusia-symptoms-coronavirus-disease>. Accessed Jun 1, 2020.
  144. Sociedad Española de Neurología. Recomendaciones de la Sociedad Española de Neurología (SEN) en relación con la pérdida de olfato como posible síntoma precoz de infección por COVID-19. Available at: <https://www.sen.es/noticias-y-actividades/222-noticias/covid-19-informacion-para-pacientes/2663-covid-recomendaciones-de-la-sociedad-espanola-de-neurologia-sen-en-relacion-con-la-perdida-de-olfato-como-posible-sintoma-precoz-de-infeccion-por-covid-19>. Accessed Jun 1, 2020.
  145. ENTUK. Loss of Sense of Smell as Marker of COVID-19 Infection. Available at: <https://www.entuk.org/sites/default/files/files/Loss%20of%20sense%20of%20smell%20as%20marker%20of%20COVID.pdf>. Accessed Mar 21, 2020.
  146. Vroegop AV, Eeckels AS, Van Rompaey V, Abeele DV, Schiappoli M, Alobid I, et al. COVID-19 and olfactory dysfunction—an ENT perspective to the current COVID-19 pandemic. *B-ENT* 2020;16:81–5. [CrossRef]
  147. Nunan D. Loss of smell and taste as symptoms of COVID-19: what does the evidence say?, The Centre for Evidence-Based Medicine. Available at: <https://www.cebm.net/covid-19/loss-of-smell-and-taste-as-symptoms-of-covid-19-what-does-the-evidence-say/>. Accessed 02 June 2020.
  148. Hwang CS. Olfactory neuropathy in severe acute respiratory syndrome: report of A case. *Acta neurologica Taiwanica* 2006;15:26–8.
  149. Mullol J, Alobid I, Mariño-Sánchez F, Izquierdo-Domínguez A, Marin C, Klimek L, et al. The Loss of Smell and Taste in the COVID-19 Outbreak: a Tale of Many Countries. *Curr Allergy Asthma Rep* 2020;20:61. [CrossRef]
  150. Dell'Era V, Farri F, Garzaro G, Gatto M, Aluffi Valletti P, Garzaro M. Smell and taste disorders during COVID-19 outbreak: Cross-sectional study on 355 patients. *Head & Neck* 2020;42:1591–6. [CrossRef]
  151. Whitcroft KL, Hummel T. Olfactory Dysfunction in COVID-19: Diagnosis and Management. *JAMA* 2020;323:2512–4. [CrossRef]
  152. Cohen BE, Durstenfeld A, Roehm PC. Viral causes of hearing

- loss: a review for hearing health professionals. *Trends Hear* 2014;18:2331216514541361. [\[CrossRef\]](#)
153. Sriwijitalai W, Wiwanitkit V. Hearing loss and COVID-19: A note. *Am J Otolaryngol* 2020;41:102473. [\[CrossRef\]](#)
  154. Rhman SA, Wahid AA. COVID-19 and sudden sensorineural hearing loss: a case report. *Otolaryngol Case Reports* 2020;16:100198. [\[CrossRef\]](#)
  155. Kilic O, Kalcioğlu MT, Cag Y, Tuysuz O, Pektas E, Caskurlu H, et al. Could sudden sensorineural hearing loss be the sole manifestation of COVID-19? An investigation into SARS-CoV-2 in the etiology of sudden sensorineural hearing loss. *Int J Infect Dis* 2020;97:208–11. [\[CrossRef\]](#)
  156. Mustafa MWM. Audiological profile of asymptomatic COVID-19 PCR-positive cases. *Am J Otolaryngol* 2020;41:102483.
  157. Degen C, Lenarz T, Willenborg K. Acute profound sensorineural hearing loss after COVID-19 pneumonia. *Mayo Clin Proc* 2020;95:1801–3. [\[CrossRef\]](#)
  158. Koumpa FS, Forde CT, Manjaly JG. Sudden irreversible hearing loss post COVID-19. *BMJ Case Rep* 2020;13:e238419.
  159. Cui C, Yao Q, Zhang D, Zhao Y, Zhang K, Nisenbaum E, et al. Approaching Otolaryngology Patients During the COVID-19 Pandemic. *Otolaryngol Head Neck Surg* 2020;163:121–31.
  160. García-Romo E, Blanco R, Nicholls C, Hernández-Tejero A, Fernández-de-Arévalo B. COVID-19 presenting with nystagmus. *Arch Soc Esp Oftalmol*. 2020 Nov 6. doi: 10.1016/j.oftal.2020.09.008. [Epub ahead of print]. [\[CrossRef\]](#)
  161. Chirakkal P, Hail ANA, Zada N, Vijayakumar DS. COVID-19 and Tinnitus. *Ear Nose Throat J*. 2020 Dec 4:145561320974849. doi: 10.1177/0145561320974849. [Epub ahead of print].
  162. Brody RM, Albergetti WG, Shimunov D, Nicoli E, Patel UA, Harris BN, et al. Changes in head and neck oncologic practice during the COVID-19 pandemic. *Head Neck* 2020;42:1448–53. [\[CrossRef\]](#)
  163. Dejucq N, Jégou B. Viruses in the mammalian male genital tract and their effects on the reproductive system. *Microbiol Mol Biol Rev* 2001;65:208–31; first and second pages, table of contents. [\[CrossRef\]](#)
  164. Liu W, Han R, Wu H, Han D. Viral threat to male fertility. *Andrologia* 2018;50:e13140. [\[CrossRef\]](#)
  165. Salam AP, Horby PW. The Breadth of Viruses in Human Semen. *Emerging infectious diseases* 2017;23:1922–4. [\[CrossRef\]](#)
  166. Jiang XH, Bukhari I, Zheng W, Yin S, Wang Z, Cooke HJ, et al. Blood-testis barrier and spermatogenesis: lessons from genetically-modified mice. *Asian journal of andrology* 2014;16:572–80. [\[CrossRef\]](#)
  167. Wang Z, Xu X. scRNA-seq Profiling of Human Testes Reveals the Presence of the ACE2 Receptor, A Target for SARS-CoV-2 Infection in Spermatogonia, Leydig and Sertoli Cells. *Cells* 2020;9:920. [\[CrossRef\]](#)
  168. Xu J, Qi L, Chi X, Yang J, Wei X, Gong E, et al. Orchitis: a complication of severe acute respiratory syndrome (SARS). *Biology of reproduction* 2006;74:410–6. [\[CrossRef\]](#)
  169. Xu J, Xu Z, Jiang Y, Qian X, Huang Y. Cryptorchidism induces mouse testicular germ cell apoptosis and changes in bcl-2 and bax protein expression. *Journal of environmental pathology, toxicology and oncology : official organ of the International Society for Environmental Toxicology and Cancer* 2000;19:25–33.
  170. Corona G, Baldi E, Isidori AM, Paoli D, Pallotti F, De Santis L, et al. SARS-CoV-2 infection, male fertility and sperm cryopreservation: a position statement of the Italian Society of Andrology and Sexual Medicine (SIAMS) (Società Italiana di Andrologia e Medicina della Sessualità). *Journal of endocrinological investigation* 2020;43:1153–7. [\[CrossRef\]](#)
  171. Li D, Jin M, Bao P, Zhao W, Zhang S. Clinical Characteristics and Results of Semen Tests Among Men With Coronavirus Disease 2019. *JAMA network open* 2020;3:e208292. [\[CrossRef\]](#)
  172. Pan F, Xiao X, Guo J, Song Y, Li H, Patel DP, et al. No evidence of severe acute respiratory syndrome-coronavirus 2 in semen of males recovering from coronavirus disease 2019. *Fertility and sterility* 2020;113:1135–9. [\[CrossRef\]](#)
  173. Holtmann N, Edimiris P, Andree M, Doehmen C, Baston-Buest D, Adams O, et al. Assessment of SARS-CoV-2 in human semen-a cohort study. *Fertility and sterility*. 2020;114:233–8.
  174. Chen F, Lou D. Rising Concern on Damaged Testis of COVID-19 Patients. *Urology* 2020;142:42. [\[CrossRef\]](#)
  175. Yang M, Chen S, Huang B, Zhong JM, Su H, Chen YJ, et al. Pathological Findings in the Testes of COVID-19 Patients: Clinical Implications. *European urology focus* 2020;6:1124–9.
  176. Garg S, Garg M, Prabhakar N, Malhotra P, Agarwal R. Unraveling the mystery of COVID-19 cytokine storm: From skin to organ systems. *Dermatol Ther*. 2020 Jun 19:e13859. doi: 10.1111/dth.13859. [Epub ahead of print]. [\[CrossRef\]](#)
  177. Bandhala Rajan M, Kumar-M P, Bhardwaj A. The trend of cutaneous lesions during COVID-19 pandemic: lessons from a meta-analysis and systematic review. *Int J Dermatol*. 2020 Sep 16. doi: 10.1111/ijd.15154. Epub ahead of print. [\[CrossRef\]](#)
  178. Daneshgaran G, Dubin DP, Gould DJ. Cutaneous Manifestations of COVID-19: An Evidence-Based Review. *Am J Clin Dermatol* 2020;21:627–39. [\[CrossRef\]](#)
  179. Sachdeva M, Mufti A, Maliyar K, Lytvyn Y, Yeung J. Hydroxychloroquine effects on psoriasis: A systematic review and a cautionary note for COVID-19 treatment. *J Am Acad Dermatol* 2020;83:579–86. [\[CrossRef\]](#)
  180. Nasiri S, Araghi F, Tabary M, Gheisari M, Mahboubi-Fooladi Z, Dadkhahfar S. A challenging case of psoriasis flare-up after COVID-19 infection. *J Dermatolog Treat* 2020;31:448–9.
  181. Wollina U. Challenges of COVID-19 pandemic for dermatology. *Dermatol Ther* 2020;33:e13430. [\[CrossRef\]](#)
  182. Zhang Y, Geng X, Tan Y, Li Q, Xu C, Xu J, et al. New understanding of the damage of SARS-CoV-2 infection outside the respiratory system. *Biomedicine & Pharmacotherapy*



- 2020;127:110195. [\[CrossRef\]](#)
183. Reis FM, Bouissou DR, Pereira VM, Camargos AF, dos Reis AM, Santos RA. Angiotensin-(1-7), its receptor Mas, and the angiotensin-converting enzyme type 2 are expressed in the human ovary. *Fertil Steril* 2011;95:176–81. [\[CrossRef\]](#)
  184. Sugino N, Suzuki T, Sakata A, Miwa I, Asada H, Taketani T, et al. Angiogenesis in the human corpus luteum: changes in expression of angiopoietins in the corpus luteum throughout the menstrual cycle and in early pregnancy. *J Clin Endocrinol Metab* 2005;90:6141–8. [\[CrossRef\]](#)
  185. Mauvais-Jarvis F, Klein SL, Levin ER. Estradiol, Progesteron, İmmünomodülasyon ve COVID-19 Sonuçları. *Endokrinoloji* 2020;161:bqaa127. [\[CrossRef\]](#)
  186. Wu YT, Liu C, Dong L, Zhang CJ, Chen Y, Liu J, et al. Viral Shedding of COVID-19 in Pregnant Women. SSRN. 2020 Mar 25. Doi: <http://dx.doi.org/10.2139/ssrn.3562059>. [Epub ahead of print]. [\[CrossRef\]](#)
  187. Merrill DC, Karoly M, Chen K, Ferrario CM, Brosnihan KB. Angiotensin-(1-7) in normal and preeclamptic pregnancy. *Endocrine* 2002;18:239–45. [\[CrossRef\]](#)
  188. Crimi E, Benincasa G, Figueroa-Marrero N, Galdiero M, Napoli C. Epigenetic susceptibility to severe respiratory viral infections and its therapeutic implications: a narrative review. *British Journal of Anaesthesia* 2020;125:1002e1017.
  189. Choudhary S, Sreenivasulu K, Mitra P, Misra S, Sharma P. Role of Genetic Variants and Gene Expression in the Susceptibility and Severity of COVID-19. *Ann Lab Med* 2021;41:129–38.
  190. Atlante S, Mongelli A, Barbi V, Martelli F, Farsetti A, Gaetano C. The epigenetic implication in coronavirus infection and therapy. *Clin Epigenetics* 2020;12:156. [\[CrossRef\]](#)
  191. Freitas NL, Azevedo PRG, Brandão F. A glance upon Epigenetic and COVID-19. *An Acad Bras Cienc* 2020;92:e20201451.
  192. Chlamydas S, Papavassiliou AG, Piperi C. Epigenetic mechanisms regulating COVID-19 infection. *Epigenetics* 2020;1–8.
  193. Thierry AR. Host/genetic factors associated with COVID-19 call for precision medicine . *Precision Clinical Medicine* 2020;3:228–34. [\[CrossRef\]](#)
  194. Pollitt KJG, Peccia J, Ko AI, Albert IK, Kaminski N, Cruz CSD, et al. COVID-19 vulnerability: the potential impact of genetic susceptibility and airborne transmission. *Hum Genomics* 2020;14:17. [\[CrossRef\]](#)
  195. Hamam JH, Palaniyar N. Post-Translational Modifications in NETosis and NETs-Mediated Diseases. *Biomolecules* 2019;9:369. [\[CrossRef\]](#)
  196. Kaplan MJ, Radic M. Neutrophil extracellular traps (NETs): Double-edged swords of innate immunity. *J Immunol* 2012;189:2689–95. [\[CrossRef\]](#)
  197. Halpin SJ, McIvor C, Whyatt G, Adams A, Harvey O, McLean L, et al. Postdischarge symptoms and rehabilitation needs in survivors of COVID-19 infection: A cross-sectional evaluation. *J Med Virol* 2020;93:1013–22. [\[CrossRef\]](#)
  198. (Jiang DH, McCoy RG. Planning for the Post-COVID Syndrome: How Payers Can Mitigate Long-Term Complications of the Pandemic. *J Gen Intern Med* 2020;35(10):3036–9. [\[CrossRef\]](#)
  199. Ahmad T, Haroon, Baig M, Hui J. Coronavirus Disease 2019 (COVID-19) Pandemic and Economic Impact. *Pak J Med Sci* 2020;36:73–8. [\[CrossRef\]](#)