

ORIGINAL RESEARCH ARTICLE

Causal association between constipation and white matter microstructure: A Mendelian randomization study

Supplementary Files

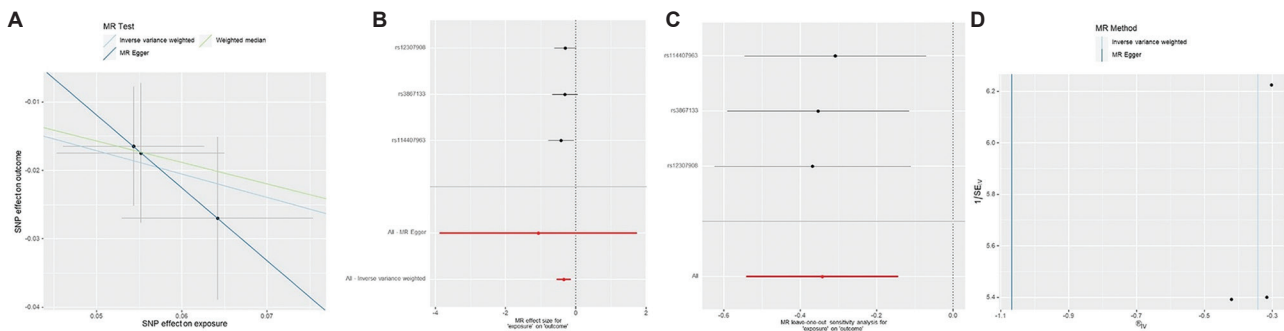


Figure S1. Complementary MR analyses reveal that the second PC of MD in the SLF has a significant protective effect against constipation. (A) Scatter plot. (B) Funnel plot. (C) Leave-one-out test. (D) Forest plot.

Abbreviations: IVW: Inverse variance weighted; MD: Mean diffusivity; MR: Mendelian randomization; PC: Principal component; SLF: Superior longitudinal fasciculus; SNP: Single nucleotide polymorphism.

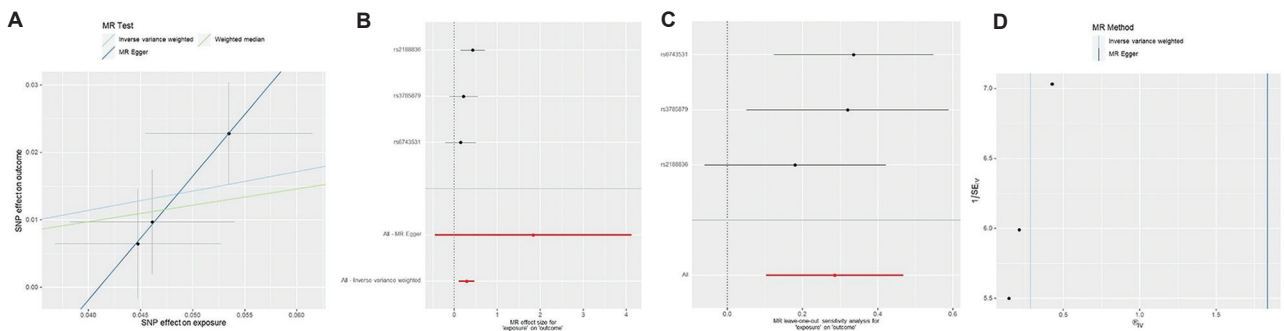


Figure S2. Complementary MR analyses reveal that the fifth PC of fractional anisotropy in the ACR is associated with an increased risk of constipation. (A) Scatter plot. (B) Funnel plot. (C) Leave-one-out test. (D) Forest plot.

Abbreviations: ACR: Anterior corona radiata; IVW: Inverse variance weighted; FA: Fractional anisotropy; MR: Mendelian randomization; PC: Principal component; SNP: Single nucleotide polymorphism.

Table S1. Information about the DTI parameters and WM tracts used in this study

ID	Phenocode	Meaning	Classification
ad.pheno1	AD_ACR_PC1	First AD PC in anterior corona radiata	Diffusion MR
ad.pheno2	AD_ACR_PC2	Second AD PC in the anterior corona radiata	Diffusion MR
ad.pheno3	AD_ACR_PC3	Third AD PC in the anterior corona radiata	Diffusion MR
ad.pheno4	AD_ACR_PC4	Fourth AD PC in the anterior corona radiata	Diffusion MR
ad.pheno5	AD_ACR_PC5	Fifth AD PC in the anterior corona radiata	Diffusion MR
ad.pheno6	AD_ALIC_PC1	First AD PC in the anterior limb of the internal capsule	Diffusion MR
ad.pheno7	AD_ALIC_PC2	Second AD PC in the anterior limb of the internal capsule	Diffusion MR
ad.pheno8	AD_ALIC_PC3	Third AD PC in the anterior limb of the internal capsule	Diffusion MR
ad.pheno9	AD_ALIC_PC4	Fourth AD PC in the anterior limb of the internal capsule	Diffusion MR
ad.pheno10	AD_ALIC_PC5	Fifth AD PC in the anterior limb of the internal capsule	Diffusion MR
ad.pheno11	AD_BCC_PC1	First AD PC in the body of corpus callosum	Diffusion MR
ad.pheno12	AD_BCC_PC2	Second AD PC in the body of corpus callosum	Diffusion MR
ad.pheno13	AD_BCC_PC3	Third AD PC in the body of corpus callosum	Diffusion MR
ad.pheno14	AD_BCC_PC4	Fourth AD PC in the body of corpus callosum	Diffusion MR
ad.pheno15	AD_BCC_PC5	Fifth AD PC in the body of corpus callosum	Diffusion MR
ad.pheno16	AD_CGC_PC1	First AD PC in cingulum (cingulate gyrus)	Diffusion MR
ad.pheno17	AD_CGC_PC2	Second AD PC in cingulum (cingulate gyrus)	Diffusion MR
ad.pheno18	AD_CGC_PC3	Third AD PC in cingulum (cingulate gyrus)	Diffusion MR
ad.pheno19	AD_CGC_PC4	Fourth AD PC in cingulum (cingulate gyrus)	Diffusion MR
ad.pheno20	AD_CGC_PC5	Fifth AD PC in cingulum (cingulate gyrus)	Diffusion MR
ad.pheno21	AD_CGH_PC1	First AD PC in cingulum (hippocampus)	Diffusion MR
ad.pheno22	AD_CGH_PC2	Second AD PC in cingulum (hippocampus)	Diffusion MR
ad.pheno23	AD_CGH_PC3	Third AD PC in cingulum (hippocampus)	Diffusion MR
ad.pheno24	AD_CGH_PC4	Fourth AD PC in cingulum (hippocampus)	Diffusion MR
ad.pheno25	AD_CGH_PC5	Fifth AD PC in cingulum (hippocampus)	Diffusion MR
ad.pheno26	AD_CST_PC1	First AD PC in corticospinal tract	Diffusion MR
ad.pheno27	AD_CST_PC2	Second AD PC in corticospinal tract	Diffusion MR
ad.pheno28	AD_CST_PC3	Third AD PC in corticospinal tract	Diffusion MR
ad.pheno29	AD_CST_PC4	Fourth AD PC in corticospinal tract	Diffusion MR
ad.pheno30	AD_CST_PC5	Fifth AD PC in corticospinal tract	Diffusion MR
ad.pheno31	AD_EC_PC1	First AD PC in the external capsule	Diffusion MR
ad.pheno32	AD_EC_PC2	Second AD PC in the external capsule	Diffusion MR
ad.pheno33	AD_EC_PC3	Third AD PC in the external capsule	Diffusion MR
ad.pheno34	AD_EC_PC4	Fourth AD PC in the external capsule	Diffusion MR
ad.pheno35	AD_EC_PC5	Fifth AD PC in the external capsule	Diffusion MR
ad.pheno36	AD_FX_PC1	First AD PC in fornix (column and body of fornix)	Diffusion MR
ad.pheno37	AD_FX_PC2	Second AD PC in fornix (column and body of fornix)	Diffusion MR
ad.pheno38	AD_FX_PC3	Third AD PC in fornix (column and body of fornix)	Diffusion MR
ad.pheno39	AD_FX_PC4	Fourth AD PC in fornix (column and body of fornix)	Diffusion MR
ad.pheno40	AD_FX_PC5	Fifth AD PC in fornix (column and body of fornix)	Diffusion MR
ad.pheno41	AD_FXST_PC1	First AD PC in fornix-stria terminalis	Diffusion MR
ad.pheno42	AD_FXST_PC2	Second AD PC in fornix-stria terminalis	Diffusion MR

(Cont'd...)

Table S1. (Continued)

ID	Phenocode	Meaning	Classification
ad.pheno43	AD_FXST_PC3	Third AD PC in fornix-stria terminalis	Diffusion MR
ad.pheno44	AD_FXST_PC4	Fourth AD PC in fornix-stria terminalis	Diffusion MR
ad.pheno45	AD_FXST_PC5	Fifth AD PC in fornix-stria terminalis	Diffusion MR
ad.pheno46	AD_GCC_PC1	First AD PC in genu of corpus callosum	Diffusion MR
ad.pheno47	AD_GCC_PC2	Second AD PC in genu of corpus callosum	Diffusion MR
ad.pheno48	AD_GCC_PC3	Third AD PC in genu of corpus callosum	Diffusion MR
ad.pheno49	AD_GCC_PC4	Fourth AD PC in genu of corpus callosum	Diffusion MR
ad.pheno50	AD_GCC_PC5	Fifth AD PC in genu of corpus callosum	Diffusion MR
ad.pheno51	AD_IFO_PC1	First AD PC in the inferior fronto-occipital fasciculus	Diffusion MR
ad.pheno52	AD_IFO_PC2	Second AD PC in the inferior fronto-occipital fasciculus	Diffusion MR
ad.pheno53	AD_IFO_PC3	Third AD PC in the inferior fronto-occipital fasciculus	Diffusion MR
ad.pheno54	AD_IFO_PC4	Fourth AD PC in the inferior fronto-occipital fasciculus	Diffusion MR
ad.pheno55	AD_IFO_PC5	Fifth AD PC in the inferior fronto-occipital fasciculus	Diffusion MR
ad.pheno56	AD_PCR_PC1	First AD PC in the posterior corona radiata	Diffusion MR
ad.pheno57	AD_PCR_PC2	Second AD PC in the posterior corona radiata	Diffusion MR
ad.pheno58	AD_PCR_PC3	Third AD PC in the posterior corona radiata	Diffusion MR
ad.pheno59	AD_PCR_PC4	Fourth AD PC in the posterior corona radiata	Diffusion MR
ad.pheno60	AD_PCR_PC5	Fifth AD PC in the posterior corona radiata	Diffusion MR
ad.pheno61	AD_PLIC_PC1	First AD PC in the posterior limb of the internal capsule	Diffusion MR
ad.pheno62	AD_PLIC_PC2	Second AD PC in the posterior limb of the internal capsule	Diffusion MR
ad.pheno63	AD_PLIC_PC3	Third AD PC in the posterior limb of the internal capsule	Diffusion MR
ad.pheno64	AD_PLIC_PC4	Fourth AD PC in the posterior limb of the internal capsule	Diffusion MR
ad.pheno65	AD_PLIC_PC5	Fifth AD PC in the posterior limb of the internal capsule	Diffusion MR
ad.pheno66	AD_PTR_PC1	First AD PC in the posterior thalamic radiation	Diffusion MR
ad.pheno67	AD_PTR_PC2	Second AD PC in the posterior thalamic radiation	Diffusion MR
ad.pheno68	AD_PTR_PC3	Third AD PC in the posterior thalamic radiation	Diffusion MR
ad.pheno69	AD_PTR_PC4	Fourth AD PC in the posterior thalamic radiation	Diffusion MR
ad.pheno70	AD_PTR_PC5	Fifth AD PC in the posterior thalamic radiation	Diffusion MR
ad.pheno71	AD_RLIC_PC1	First AD PC in retrolenticular part of the internal capsule	Diffusion MR
ad.pheno72	AD_RLIC_PC2	Second AD PC in retrolenticular part of the internal capsule	Diffusion MR
ad.pheno73	AD_RLIC_PC3	Third AD PC in retrolenticular part of the internal capsule	Diffusion MR
ad.pheno74	AD_RLIC_PC4	Fourth AD PC in retrolenticular part of the internal capsule	Diffusion MR
ad.pheno75	AD_RLIC_PC5	Fifth AD PC in retrolenticular part of the internal capsule	Diffusion MR
ad.pheno76	AD_SCC_PC1	First AD PC in the splenium of corpus callosum	Diffusion MR
ad.pheno77	AD_SCC_PC2	Second AD PC in the splenium of corpus callosum	Diffusion MR
ad.pheno78	AD_SCC_PC3	Third AD PC in the splenium of corpus callosum	Diffusion MR
ad.pheno79	AD_SCC_PC4	Fourth AD PC in the splenium of corpus callosum	Diffusion MR
ad.pheno80	AD_SCC_PC5	Fifth AD PC in the splenium of corpus callosum	Diffusion MR
ad.pheno81	AD_SCR_PC1	First AD PC in the superior corona radiata	Diffusion MR
ad.pheno82	AD_SCR_PC2	Second AD PC in the superior corona radiata	Diffusion MR
ad.pheno83	AD_SCR_PC3	Third AD PC in the superior corona radiata	Diffusion MR
ad.pheno84	AD_SCR_PC4	Fourth AD PC in the superior corona radiata	Diffusion MR

(Cont'd...)

Table S1. (Continued)

ID	Phenocode	Meaning	Classification
ad.pheno85	AD_SCR_PC5	Fifth AD PC in the superior corona radiata	Diffusion MR
ad.pheno86	AD_SFO_PC1	First AD PC in the superior fronto-occipital fasciculus	Diffusion MR
ad.pheno87	AD_SFO_PC2	Second AD PC in the superior fronto-occipital fasciculus	Diffusion MR
ad.pheno88	AD_SFO_PC3	Third AD PC in the superior fronto-occipital fasciculus	Diffusion MR
ad.pheno89	AD_SFO_PC4	Fourth AD PC in the superior fronto-occipital fasciculus	Diffusion MR
ad.pheno90	AD_SFO_PC5	Fifth AD PC in the superior fronto-occipital fasciculus	Diffusion MR
ad.pheno91	AD_SLF_PC1	First AD PC in the superior longitudinal fasciculus	Diffusion MR
ad.pheno92	AD_SLF_PC2	Second AD PC in the superior longitudinal fasciculus	Diffusion MR
ad.pheno93	AD_SLF_PC3	Third AD PC in the superior longitudinal fasciculus	Diffusion MR
ad.pheno94	AD_SLF_PC4	Fourth AD PC in the superior longitudinal fasciculus	Diffusion MR
ad.pheno95	AD_SLF_PC5	Fifth AD PC in the superior longitudinal fasciculus	Diffusion MR
ad.pheno96	AD_SS_PC1	First AD PC in the sagittal stratum	Diffusion MR
ad.pheno97	AD_SS_PC2	Second AD PC in the sagittal stratum	Diffusion MR
ad.pheno98	AD_SS_PC3	Third AD PC in the sagittal stratum	Diffusion MR
ad.pheno99	AD_SS_PC4	Fourth AD PC in the sagittal stratum	Diffusion MR
ad.pheno100	AD_SS_PC5	Fifth AD PC in the sagittal stratum	Diffusion MR
ad.pheno101	AD_UNC_PC1	First AD PC in uncinate fasciculus	Diffusion MR
ad.pheno102	AD_UNC_PC2	Second AD PC in uncinate fasciculus	Diffusion MR
ad.pheno103	AD_UNC_PC3	Third AD PC in uncinate fasciculus	Diffusion MR
ad.pheno104	AD_UNC_PC4	Fourth AD PC in uncinate fasciculus	Diffusion MR
ad.pheno105	AD_UNC_PC5	Fifth AD PC in uncinate fasciculus	Diffusion MR
fa.pheno1	FA_ACR_PC1	First FA PC in the anterior corona radiata	Diffusion MR
fa.pheno2	FA_ACR_PC2	Second FA PC in the anterior corona radiata	Diffusion MR
fa.pheno3	FA_ACR_PC3	Third FA PC in the anterior corona radiata	Diffusion MR
fa.pheno4	FA_ACR_PC4	Fourth FA PC in the anterior corona radiata	Diffusion MR
fa.pheno5	FA_ACR_PC5	Fifth FA PC in the anterior corona radiata	Diffusion MR
fa.pheno6	FA_ALIC_PC1	First FA PC in the anterior limb of the internal capsule	Diffusion MR
fa.pheno7	FA_ALIC_PC2	Second FA PC in the anterior limb of the internal capsule	Diffusion MR
fa.pheno8	FA_ALIC_PC3	Third FA PC in the anterior limb of the internal capsule	Diffusion MR
fa.pheno9	FA_ALIC_PC4	Fourth FA PC in the anterior limb of the internal capsule	Diffusion MR
fa.pheno10	FA_ALIC_PC5	Fifth FA PC in the anterior limb of the internal capsule	Diffusion MR
fa.pheno11	FA_BCC_PC1	First FA PC in the body of corpus callosum	Diffusion MR
fa.pheno12	FA_BCC_PC2	Second FA PC in the body of corpus callosum	Diffusion MR
fa.pheno13	FA_BCC_PC3	Third FA PC in the body of corpus callosum	Diffusion MR
fa.pheno14	FA_BCC_PC4	Fourth FA PC in the body of corpus callosum	Diffusion MR
fa.pheno15	FA_BCC_PC5	Fifth FA PC in the body of corpus callosum	Diffusion MR
fa.pheno16	FA_CGC_PC1	First FA PC in cingulum (cingulate gyrus)	Diffusion MR
fa.pheno17	FA_CGC_PC2	Second FA PC in cingulum (cingulate gyrus)	Diffusion MR
fa.pheno18	FA_CGC_PC3	Third FA PC in cingulum (cingulate gyrus)	Diffusion MR
fa.pheno19	FA_CGC_PC4	Fourth FA PC in cingulum (cingulate gyrus)	Diffusion MR
fa.pheno20	FA_CGC_PC5	Fifth FA PC in cingulum (cingulate gyrus)	Diffusion MR
fa.pheno21	FA_CGH_PC1	First FA PC in cingulum (hippocampus)	Diffusion MR

(Cont'd...)

Table S1. (Continued)

ID	Phenocode	Meaning	Classification
fa.pheno22	FA_CGH_PC2	Second FA PC in cingulum (hippocampus)	Diffusion MR
fa.pheno23	FA_CGH_PC3	Third FA PC in cingulum (hippocampus)	Diffusion MR
fa.pheno24	FA_CGH_PC4	Fourth FA PC in cingulum (hippocampus)	Diffusion MR
fa.pheno25	FA_CGH_PC5	Fifth FA PC in cingulum (hippocampus)	Diffusion MR
fa.pheno26	FA_CST_PC1	First FA PC in corticospinal tract	Diffusion MR
fa.pheno27	FA_CST_PC2	Second FA PC in corticospinal tract	Diffusion MR
fa.pheno28	FA_CST_PC3	Third FA PC in corticospinal tract	Diffusion MR
fa.pheno29	FA_CST_PC4	Fourth FA PC in corticospinal tract	Diffusion MR
fa.pheno30	FA_CST_PC5	Fifth FA PC in corticospinal tract	Diffusion MR
fa.pheno31	FA_EC_PC1	First FA PC in the external capsule	Diffusion MR
fa.pheno32	FA_EC_PC2	Second FA PC in the external capsule	Diffusion MR
fa.pheno33	FA_EC_PC3	Third FA PC in the external capsule	Diffusion MR
fa.pheno34	FA_EC_PC4	Fourth FA PC in the external capsule	Diffusion MR
fa.pheno35	FA_EC_PC5	Fifth FA PC in the external capsule	Diffusion MR
fa.pheno36	FA_FX_PC1	First FA PC in fornix (column and body of fornix)	Diffusion MR
fa.pheno37	FA_FX_PC2	Second FA PC in fornix (column and body of fornix)	Diffusion MR
fa.pheno38	FA_FX_PC3	Third FA PC in fornix (column and body of fornix)	Diffusion MR
fa.pheno39	FA_FX_PC4	Fourth FA PC in fornix (column and body of fornix)	Diffusion MR
fa.pheno40	FA_FX_PC5	Fifth FA PC in fornix (column and body of fornix)	Diffusion MR
fa.pheno41	FA_FXST_PC1	First FA PC in fornix-stria terminalis	Diffusion MR
fa.pheno42	FA_FXST_PC2	Second FA PC in fornix-stria terminalis	Diffusion MR
fa.pheno43	FA_FXST_PC3	Third FA PC in fornix-stria terminalis	Diffusion MR
fa.pheno44	FA_FXST_PC4	Fourth FA PC in fornix-stria terminalis	Diffusion MR
fa.pheno45	FA_FXST_PC5	Fifth FA PC in fornix-stria terminalis	Diffusion MR
fa.pheno46	FA_GCC_PC1	First FA PC in genu of corpus callosum	Diffusion MR
fa.pheno47	FA_GCC_PC2	Second FA PC in genu of corpus callosum	Diffusion MR
fa.pheno48	FA_GCC_PC3	Third FA PC in genu of corpus callosum	Diffusion MR
fa.pheno49	FA_GCC_PC4	Fourth FA PC in genu of corpus callosum	Diffusion MR
fa.pheno50	FA_GCC_PC5	Fifth FA PC in genu of corpus callosum	Diffusion MR
fa.pheno51	FA_IFO_PC1	First FA PC in the inferior fronto-occipital fasciculus	Diffusion MR
fa.pheno52	FA_IFO_PC2	Second FA PC in the inferior fronto-occipital fasciculus	Diffusion MR
fa.pheno53	FA_IFO_PC3	Third FA PC in the inferior fronto-occipital fasciculus	Diffusion MR
fa.pheno54	FA_IFO_PC4	Fourth FA PC in the inferior fronto-occipital fasciculus	Diffusion MR
fa.pheno55	FA_IFO_PC5	Fifth FA PC in the inferior fronto-occipital fasciculus	Diffusion MR
fa.pheno56	FA_PCR_PC1	First FA PC in the posterior corona radiata	Diffusion MR
fa.pheno57	FA_PCR_PC2	Second FA PC in the posterior corona radiata	Diffusion MR
fa.pheno58	FA_PCR_PC3	Third FA PC in the posterior corona radiata	Diffusion MR
fa.pheno59	FA_PCR_PC4	Fourth FA PC in the posterior corona radiata	Diffusion MR
fa.pheno60	FA_PCR_PC5	Fifth FA PC in the posterior corona radiata	Diffusion MR
fa.pheno61	FA_PLIC_PC1	First FA PC in the posterior limb of internal capsule	Diffusion MR
fa.pheno62	FA_PLIC_PC2	Second FA PC in the posterior limb of internal capsule	Diffusion MR
fa.pheno63	FA_PLIC_PC3	Third FA PC in the posterior limb of internal capsule	Diffusion MR

(Cont'd...)

Table S1. (Continued)

ID	Phenocode	Meaning	Classification
fa.pheno64	FA_PLIC_PC4	Fourth FA PC in the posterior limb of internal capsule	Diffusion MR
fa.pheno65	FA_PLIC_PC5	Fifth FA PC in the posterior limb of internal capsule	Diffusion MR
fa.pheno66	FA_PTR_PC1	First FA PC in the posterior thalamic radiation	Diffusion MR
fa.pheno67	FA_PTR_PC2	Second FA PC in the posterior thalamic radiation	Diffusion MR
fa.pheno68	FA_PTR_PC3	Third FA PC in the posterior thalamic radiation	Diffusion MR
fa.pheno69	FA_PTR_PC4	Fourth FA PC in the posterior thalamic radiation	Diffusion MR
fa.pheno70	FA_PTR_PC5	Fifth FA PC in the posterior thalamic radiation	Diffusion MR
fa.pheno71	FA_RLIC_PC1	First FA PC in retrolenticular part of internal capsule	Diffusion MR
fa.pheno72	FA_RLIC_PC2	Second FA PC in retrolenticular part of internal capsule	Diffusion MR
fa.pheno73	FA_RLIC_PC3	Third FA PC in retrolenticular part of internal capsule	Diffusion MR
fa.pheno74	FA_RLIC_PC4	Fourth FA PC in retrolenticular part of internal capsule	Diffusion MR
fa.pheno75	FA_RLIC_PC5	Fifth FA PC in retrolenticular part of internal capsule	Diffusion MR
fa.pheno76	FA_SCC_PC1	First FA PC in the splenium of corpus callosum	Diffusion MR
fa.pheno77	FA_SCC_PC2	Second FA PC in the splenium of corpus callosum	Diffusion MR
fa.pheno78	FA_SCC_PC3	Third FA PC in the splenium of corpus callosum	Diffusion MR
fa.pheno79	FA_SCC_PC4	Fourth FA PC in the splenium of corpus callosum	Diffusion MR
fa.pheno80	FA_SCC_PC5	Fifth FA PC in the splenium of corpus callosum	Diffusion MR
fa.pheno81	FA_SCR_PC1	First FA PC in the superior corona radiata	Diffusion MR
fa.pheno82	FA_SCR_PC2	Second FA PC in the superior corona radiata	Diffusion MR
fa.pheno83	FA_SCR_PC3	Third FA PC in the superior corona radiata	Diffusion MR
fa.pheno84	FA_SCR_PC4	Fourth FA PC in the superior corona radiata	Diffusion MR
fa.pheno85	FA_SCR_PC5	Fifth FA PC in the superior corona radiata	Diffusion MR
fa.pheno86	FA_SFO_PC1	First FA PC in the superior fronto-occipital fasciculus	Diffusion MR
fa.pheno87	FA_SFO_PC2	Second FA PC in the superior fronto-occipital fasciculus	Diffusion MR
fa.pheno88	FA_SFO_PC3	Third FA PC in the superior fronto-occipital fasciculus	Diffusion MR
fa.pheno89	FA_SFO_PC4	Fourth FA PC in the superior fronto-occipital fasciculus	Diffusion MR
fa.pheno90	FA_SFO_PC5	Fifth FA PC in the superior fronto-occipital fasciculus	Diffusion MR
fa.pheno91	FA_SLF_PC1	First FA PC in the superior longitudinal fasciculus	Diffusion MR
fa.pheno92	FA_SLF_PC2	Second FA PC in the superior longitudinal fasciculus	Diffusion MR
fa.pheno93	FA_SLF_PC3	Third FA PC in the superior longitudinal fasciculus	Diffusion MR
fa.pheno94	FA_SLF_PC4	Fourth FA PC in the superior longitudinal fasciculus	Diffusion MR
fa.pheno95	FA_SLF_PC5	Fifth FA PC in the superior longitudinal fasciculus	Diffusion MR
fa.pheno96	FA_SS_PC1	First FA PC in sagittal stratum	Diffusion MR
fa.pheno97	FA_SS_PC2	Second FA PC in sagittal stratum	Diffusion MR
fa.pheno98	FA_SS_PC3	Third FA PC in sagittal stratum	Diffusion MR
fa.pheno99	FA_SS_PC4	Fourth FA PC in sagittal stratum	Diffusion MR
fa.pheno100	FA_SS_PC5	Fifth FA PC in sagittal stratum	Diffusion MR
fa.pheno101	FA_UNC_PC1	First FA PC in uncinate fasciculus	Diffusion MR
fa.pheno102	FA_UNC_PC2	Second FA PC in uncinate fasciculus	Diffusion MR
fa.pheno103	FA_UNC_PC3	Third FA PC in uncinate fasciculus	Diffusion MR
fa.pheno104	FA_UNC_PC4	Fourth FA PC in uncinate fasciculus	Diffusion MR
fa.pheno105	FA_UNC_PC5	Fifth FA PC in uncinate fasciculus	Diffusion MR

(Cont'd...)

Table S1. (Continued)

ID	Phenocode	Meaning	Classification
md.pheno1	MD_ACR_PC1	First MD PC in the anterior corona radiata	Diffusion MR
md.pheno2	MD_ACR_PC2	Second MD PC in the anterior corona radiata	Diffusion MR
md.pheno3	MD_ACR_PC3	Third MD PC in the anterior corona radiata	Diffusion MR
md.pheno4	MD_ACR_PC4	Fourth MD PC in the anterior corona radiata	Diffusion MR
md.pheno5	MD_ACR_PC5	Fifth MD PC in the anterior corona radiata	Diffusion MR
md.pheno6	MD_ALIC_PC1	First MD PC in the anterior limb of internal capsule	Diffusion MR
md.pheno7	MD_ALIC_PC2	Second MD PC in the anterior limb of internal capsule	Diffusion MR
md.pheno8	MD_ALIC_PC3	Third MD PC in the anterior limb of internal capsule	Diffusion MR
md.pheno9	MD_ALIC_PC4	Fourth MD PC in the anterior limb of internal capsule	Diffusion MR
md.pheno10	MD_ALIC_PC5	Fifth MD PC in the anterior limb of internal capsule	Diffusion MR
md.pheno11	MD_BCC_PC1	First MD PC in body of corpus callosum	Diffusion MR
md.pheno12	MD_BCC_PC2	Second MD PC in body of corpus callosum	Diffusion MR
md.pheno13	MD_BCC_PC3	Third MD PC in body of corpus callosum	Diffusion MR
md.pheno14	MD_BCC_PC4	Fourth MD PC in body of corpus callosum	Diffusion MR
md.pheno15	MD_BCC_PC5	Fifth MD PC in body of corpus callosum	Diffusion MR
md.pheno16	MD_CGC_PC1	First MD PC in cingulum (cingulate gyrus)	Diffusion MR
md.pheno17	MD_CGC_PC2	Second MD PC in cingulum (cingulate gyrus)	Diffusion MR
md.pheno18	MD_CGC_PC3	Third MD PC in cingulum (cingulate gyrus)	Diffusion MR
md.pheno19	MD_CGC_PC4	Fourth MD PC in cingulum (cingulate gyrus)	Diffusion MR
md.pheno20	MD_CGC_PC5	Fifth MD PC in cingulum (cingulate gyrus)	Diffusion MR
md.pheno21	MD_CGH_PC1	First MD PC in cingulum (hippocampus)	Diffusion MR
md.pheno22	MD_CGH_PC2	Second MD PC in cingulum (hippocampus)	Diffusion MR
md.pheno23	MD_CGH_PC3	Third MD PC in cingulum (hippocampus)	Diffusion MR
md.pheno24	MD_CGH_PC4	Fourth MD PC in cingulum (hippocampus)	Diffusion MR
md.pheno25	MD_CGH_PC5	Fifth MD PC in cingulum (hippocampus)	Diffusion MR
md.pheno26	MD_CST_PC1	First MD PC in corticospinal tract	Diffusion MR
md.pheno27	MD_CST_PC2	Second MD PC in corticospinal tract	Diffusion MR
md.pheno28	MD_CST_PC3	Third MD PC in corticospinal tract	Diffusion MR
md.pheno29	MD_CST_PC4	Fourth MD PC in corticospinal tract	Diffusion MR
md.pheno30	MD_CST_PC5	Fifth MD PC in corticospinal tract	Diffusion MR
md.pheno31	MD_EC_PC1	First MD PC in external capsule	Diffusion MR
md.pheno32	MD_EC_PC2	Second MD PC in external capsule	Diffusion MR
md.pheno33	MD_EC_PC3	Third MD PC in external capsule	Diffusion MR
md.pheno34	MD_EC_PC4	Fourth MD PC in external capsule	Diffusion MR
md.pheno35	MD_EC_PC5	Fifth MD PC in external capsule	Diffusion MR
md.pheno36	MD_FX_PC1	First MD PC in fornix (column and body of fornix)	Diffusion MR
md.pheno37	MD_FX_PC2	Second MD PC in fornix (column and body of fornix)	Diffusion MR
md.pheno38	MD_FX_PC3	Third MD PC in fornix (column and body of fornix)	Diffusion MR
md.pheno39	MD_FX_PC4	Fourth MD PC in fornix (column and body of fornix)	Diffusion MR
md.pheno40	MD_FX_PC5	Fifth MD PC in fornix (column and body of fornix)	Diffusion MR
md.pheno41	MD_FXST_PC1	First MD PC in fornix-stria terminalis	Diffusion MR
md.pheno42	MD_FXST_PC2	Second MD PC in fornix-stria terminalis	Diffusion MR

(Cont'd...)

Table S1. (Continued)

ID	Phenocode	Meaning	Classification
md.pheno43	MD_FXST_PC3	Third MD PC in fornix-stria terminalis	Diffusion MR
md.pheno44	MD_FXST_PC4	Fourth MD PC in fornix-stria terminalis	Diffusion MR
md.pheno45	MD_FXST_PC5	Fifth MD PC in fornix-stria terminalis	Diffusion MR
md.pheno46	MD_GCC_PC1	First MD PC in genu of corpus callosum	Diffusion MR
md.pheno47	MD_GCC_PC2	Second MD PC in genu of corpus callosum	Diffusion MR
md.pheno48	MD_GCC_PC3	Third MD PC in genu of corpus callosum	Diffusion MR
md.pheno49	MD_GCC_PC4	Fourth MD PC in genu of corpus callosum	Diffusion MR
md.pheno50	MD_GCC_PC5	Fifth MD PC in genu of corpus callosum	Diffusion MR
md.pheno51	MD_IFO_PC1	First MD PC in the inferior fronto-occipital fasciculus	Diffusion MR
md.pheno52	MD_IFO_PC2	Second MD PC in the inferior fronto-occipital fasciculus	Diffusion MR
md.pheno53	MD_IFO_PC3	Third MD PC in the inferior fronto-occipital fasciculus	Diffusion MR
md.pheno54	MD_IFO_PC4	Fourth MD PC in the inferior fronto-occipital fasciculus	Diffusion MR
md.pheno55	MD_IFO_PC5	Fifth MD PC in the inferior fronto-occipital fasciculus	Diffusion MR
md.pheno56	MD_PCR_PC1	First MD PC in the posterior corona radiata	Diffusion MR
md.pheno57	MD_PCR_PC2	Second MD PC in the posterior corona radiata	Diffusion MR
md.pheno58	MD_PCR_PC3	Third MD PC in the posterior corona radiata	Diffusion MR
md.pheno59	MD_PCR_PC4	Fourth MD PC in the posterior corona radiata	Diffusion MR
md.pheno60	MD_PCR_PC5	Fifth MD PC in the posterior corona radiata	Diffusion MR
md.pheno61	MD_PLIC_PC1	First MD PC in the posterior limb of internal capsule	Diffusion MR
md.pheno62	MD_PLIC_PC2	Second MD PC in the posterior limb of internal capsule	Diffusion MR
md.pheno63	MD_PLIC_PC3	Third MD PC in the posterior limb of internal capsule	Diffusion MR
md.pheno64	MD_PLIC_PC4	Fourth MD PC in the posterior limb of internal capsule	Diffusion MR
md.pheno65	MD_PLIC_PC5	Fifth MD PC in the posterior limb of internal capsule	Diffusion MR
md.pheno66	MD_PTR_PC1	First MD PC in the posterior thalamic radiation	Diffusion MR
md.pheno67	MD_PTR_PC2	Second MD PC in the posterior thalamic radiation	Diffusion MR
md.pheno68	MD_PTR_PC3	Third MD PC in the posterior thalamic radiation	Diffusion MR
md.pheno69	MD_PTR_PC4	Fourth MD PC in the posterior thalamic radiation	Diffusion MR
md.pheno70	MD_PTR_PC5	Fifth MD PC in the posterior thalamic radiation	Diffusion MR
md.pheno71	MD_RLIC_PC1	First MD PC in retrolenticular part of internal capsule	Diffusion MR
md.pheno72	MD_RLIC_PC2	Second MD PC in retrolenticular part of internal capsule	Diffusion MR
md.pheno73	MD_RLIC_PC3	Third MD PC in retrolenticular part of internal capsule	Diffusion MR
md.pheno74	MD_RLIC_PC4	Fourth MD PC in retrolenticular part of internal capsule	Diffusion MR
md.pheno75	MD_RLIC_PC5	Fifth MD PC in retrolenticular part of internal capsule	Diffusion MR
md.pheno76	MD_SCC_PC1	First MD PC in the splenium of corpus callosum	Diffusion MR
md.pheno77	MD_SCC_PC2	Second MD PC in the splenium of corpus callosum	Diffusion MR
md.pheno78	MD_SCC_PC3	Third MD PC in the splenium of corpus callosum	Diffusion MR
md.pheno79	MD_SCC_PC4	Fourth MD PC in the splenium of corpus callosum	Diffusion MR
md.pheno80	MD_SCC_PC5	Fifth MD PC in the splenium of corpus callosum	Diffusion MR
md.pheno81	MD_SCR_PC1	First MD PC in the superior corona radiata	Diffusion MR
md.pheno82	MD_SCR_PC2	Second MD PC in the superior corona radiata	Diffusion MR
md.pheno83	MD_SCR_PC3	Third MD PC in the superior corona radiata	Diffusion MR
md.pheno84	MD_SCR_PC4	Fourth MD PC in the superior corona radiata	Diffusion MR

(Cont'd...)

Table S1. (Continued)

ID	Phenocode	Meaning	Classification
md.pheno85	MD_SCR_PC5	Fifth MD PC in the superior corona radiata	Diffusion MR
md.pheno86	MD_SFO_PC1	First MD PC in the superior fronto-occipital fasciculus	Diffusion MR
md.pheno87	MD_SFO_PC2	Second MD PC in the superior fronto-occipital fasciculus	Diffusion MR
md.pheno88	MD_SFO_PC3	Third MD PC in the superior fronto-occipital fasciculus	Diffusion MR
md.pheno89	MD_SFO_PC4	Fourth MD PC in the superior fronto-occipital fasciculus	Diffusion MR
md.pheno90	MD_SFO_PC5	Fifth MD PC in the superior fronto-occipital fasciculus	Diffusion MR
md.pheno91	MD_SLF_PC1	First MD PC in the superior longitudinal fasciculus	Diffusion MR
md.pheno92	MD_SLF_PC2	Second MD PC in the superior longitudinal fasciculus	Diffusion MR
md.pheno93	MD_SLF_PC3	Third MD PC in the superior longitudinal fasciculus	Diffusion MR
md.pheno94	MD_SLF_PC4	Fourth MD PC in the superior longitudinal fasciculus	Diffusion MR
md.pheno95	MD_SLF_PC5	Fifth MD PC in the superior longitudinal fasciculus	Diffusion MR
md.pheno96	MD_SS_PC1	First MD PC in sagittal stratum	Diffusion MR
md.pheno97	MD_SS_PC2	Second MD PC in sagittal stratum	Diffusion MR
md.pheno98	MD_SS_PC3	Third MD PC in sagittal stratum	Diffusion MR
md.pheno99	MD_SS_PC4	Fourth MD PC in sagittal stratum	Diffusion MR
md.pheno100	MD_SS_PC5	Fifth MD PC in sagittal stratum	Diffusion MR
md.pheno101	MD_UNC_PC1	First MD PC in uncinate fasciculus	Diffusion MR
md.pheno102	MD_UNC_PC2	Second MD PC in uncinate fasciculus	Diffusion MR
md.pheno103	MD_UNC_PC3	Third MD PC in uncinate fasciculus	Diffusion MR
md.pheno104	MD_UNC_PC4	Fourth MD PC in uncinate fasciculus	Diffusion MR
md.pheno105	MD_UNC_PC5	Fifth MD PC in uncinate fasciculus	Diffusion MR
mo.pheno1	MO_ACR_PC1	First MO PC in the anterior corona radiata	Diffusion MR
mo.pheno2	MO_ACR_PC2	Second MO PC in the anterior corona radiata	Diffusion MR
mo.pheno3	MO_ACR_PC3	Third MO PC in the anterior corona radiata	Diffusion MR
mo.pheno4	MO_ACR_PC4	Fourth MO PC in the anterior corona radiata	Diffusion MR
mo.pheno5	MO_ACR_PC5	Fifth MO PC in the anterior corona radiata	Diffusion MR
mo.pheno6	MO_ALIC_PC1	First MO PC in the anterior limb of internal capsule	Diffusion MR
mo.pheno7	MO_ALIC_PC2	Second MO PC in the anterior limb of internal capsule	Diffusion MR
mo.pheno8	MO_ALIC_PC3	Third MO PC in the anterior limb of internal capsule	Diffusion MR
mo.pheno9	MO_ALIC_PC4	Fourth MO PC in the anterior limb of internal capsule	Diffusion MR
mo.pheno10	MO_ALIC_PC5	Fifth MO PC in the anterior limb of internal capsule	Diffusion MR
mo.pheno11	MO_BCC_PC1	First MO PC in body of corpus callosum	Diffusion MR
mo.pheno12	MO_BCC_PC2	Second MO PC in body of corpus callosum	Diffusion MR
mo.pheno13	MO_BCC_PC3	Third MO PC in body of corpus callosum	Diffusion MR
mo.pheno14	MO_BCC_PC4	Fourth MO PC in body of corpus callosum	Diffusion MR
mo.pheno15	MO_BCC_PC5	Fifth MO PC in body of corpus callosum	Diffusion MR
mo.pheno16	MO_CGC_PC1	First MO PC in cingulum (cingulate gyrus)	Diffusion MR
mo.pheno17	MO_CGC_PC2	Second MO PC in cingulum (cingulate gyrus)	Diffusion MR
mo.pheno18	MO_CGC_PC3	Third MO PC in cingulum (cingulate gyrus)	Diffusion MR
mo.pheno19	MO_CGC_PC4	Fourth MO PC in cingulum (cingulate gyrus)	Diffusion MR
mo.pheno20	MO_CGC_PC5	Fifth MO PC in cingulum (cingulate gyrus)	Diffusion MR
mo.pheno21	MO_CGH_PC1	First MO PC in cingulum (hippocampus)	Diffusion MR

(Cont'd...)

Table S1. (Continued)

ID	Phenocode	Meaning	Classification
mo.pheno22	MO_CGH_PC2	Second MO PC in cingulum (hippocampus)	Diffusion MR
mo.pheno23	MO_CGH_PC3	Third MO PC in cingulum (hippocampus)	Diffusion MR
mo.pheno24	MO_CGH_PC4	Fourth MO PC in cingulum (hippocampus)	Diffusion MR
mo.pheno25	MO_CGH_PC5	Fifth MO PC in cingulum (hippocampus)	Diffusion MR
mo.pheno26	MO_CST_PC1	First MO PC in corticospinal tract	Diffusion MR
mo.pheno27	MO_CST_PC2	Second MO PC in corticospinal tract	Diffusion MR
mo.pheno28	MO_CST_PC3	Third MO PC in corticospinal tract	Diffusion MR
mo.pheno29	MO_CST_PC4	Fourth MO PC in corticospinal tract	Diffusion MR
mo.pheno30	MO_CST_PC5	Fifth MO PC in corticospinal tract	Diffusion MR
mo.pheno31	MO_EC_PC1	First MO PC in external capsule	Diffusion MR
mo.pheno32	MO_EC_PC2	Second MO PC in external capsule	Diffusion MR
mo.pheno33	MO_EC_PC3	Third MO PC in external capsule	Diffusion MR
mo.pheno34	MO_EC_PC4	Fourth MO PC in external capsule	Diffusion MR
mo.pheno35	MO_EC_PC5	Fifth MO PC in external capsule	Diffusion MR
mo.pheno36	MO_FX_PC1	First MO PC in fornix (column and body of fornix)	Diffusion MR
mo.pheno37	MO_FX_PC2	Second MO PC in fornix (column and body of fornix)	Diffusion MR
mo.pheno38	MO_FX_PC3	Third MO PC in fornix (column and body of fornix)	Diffusion MR
mo.pheno39	MO_FX_PC4	Fourth MO PC in fornix (column and body of fornix)	Diffusion MR
mo.pheno40	MO_FX_PC5	Fifth MO PC in fornix (column and body of fornix)	Diffusion MR
mo.pheno41	MO_FXST_PC1	First MO PC in fornix-stria terminalis	Diffusion MR
mo.pheno42	MO_FXST_PC2	Second MO PC in fornix-stria terminalis	Diffusion MR
mo.pheno43	MO_FXST_PC3	Third MO PC in fornix-stria terminalis	Diffusion MR
mo.pheno44	MO_FXST_PC4	Fourth MO PC in fornix-stria terminalis	Diffusion MR
mo.pheno45	MO_FXST_PC5	Fifth MO PC in fornix-stria terminalis	Diffusion MR
mo.pheno46	MO_GCC_PC1	First MO PC in genu of corpus callosum	Diffusion MR
mo.pheno47	MO_GCC_PC2	Second MO PC in genu of corpus callosum	Diffusion MR
mo.pheno48	MO_GCC_PC3	Third MO PC in genu of corpus callosum	Diffusion MR
mo.pheno49	MO_GCC_PC4	Fourth MO PC in genu of corpus callosum	Diffusion MR
mo.pheno50	MO_GCC_PC5	Fifth MO PC in genu of corpus callosum	Diffusion MR
mo.pheno51	MO_IFO_PC1	First MO PC in the inferior fronto-occipital fasciculus	Diffusion MR
mo.pheno52	MO_IFO_PC2	Second MO PC in the inferior fronto-occipital fasciculus	Diffusion MR
mo.pheno53	MO_IFO_PC3	Third MO PC in the inferior fronto-occipital fasciculus	Diffusion MR
mo.pheno54	MO_IFO_PC4	Fourth MO PC in the inferior fronto-occipital fasciculus	Diffusion MR
mo.pheno55	MO_IFO_PC5	Fifth MO PC in the inferior fronto-occipital fasciculus	Diffusion MR
mo.pheno56	MO_PCR_PC1	First MO PC in the posterior corona radiata	Diffusion MR
mo.pheno57	MO_PCR_PC2	Second MO PC in the posterior corona radiata	Diffusion MR
mo.pheno58	MO_PCR_PC3	Third MO PC in the posterior corona radiata	Diffusion MR
mo.pheno59	MO_PCR_PC4	Fourth MO PC in the posterior corona radiata	Diffusion MR
mo.pheno60	MO_PCR_PC5	Fifth MO PC in the posterior corona radiata	Diffusion MR
mo.pheno61	MO_PLIC_PC1	First MO PC in the posterior limb of internal capsule	Diffusion MR
mo.pheno62	MO_PLIC_PC2	Second MO PC in the posterior limb of internal capsule	Diffusion MR
mo.pheno63	MO_PLIC_PC3	Third MO PC in the posterior limb of internal capsule	Diffusion MR

(Cont'd...)

Table S1. (Continued)

ID	Phenocode	Meaning	Classification
mo.pheno64	MO_PLIC_PC4	Fourth MO PC in the posterior limb of internal capsule	Diffusion MR
mo.pheno65	MO_PLIC_PC5	Fifth MO PC in the posterior limb of internal capsule	Diffusion MR
mo.pheno66	MO_PTR_PC1	First MO PC in the posterior thalamic radiation	Diffusion MR
mo.pheno67	MO_PTR_PC2	Second MO PC in the posterior thalamic radiation	Diffusion MR
mo.pheno68	MO_PTR_PC3	Third MO PC in the posterior thalamic radiation	Diffusion MR
mo.pheno69	MO_PTR_PC4	Fourth MO PC in the posterior thalamic radiation	Diffusion MR
mo.pheno70	MO_PTR_PC5	Fifth MO PC in the posterior thalamic radiation	Diffusion MR
mo.pheno71	MO_RLIC_PC1	First MO PC in retrolenticular part of internal capsule	Diffusion MR
mo.pheno72	MO_RLIC_PC2	Second MO PC in retrolenticular part of internal capsule	Diffusion MR
mo.pheno73	MO_RLIC_PC3	Third MO PC in retrolenticular part of internal capsule	Diffusion MR
mo.pheno74	MO_RLIC_PC4	Fourth MO PC in retrolenticular part of internal capsule	Diffusion MR
mo.pheno75	MO_RLIC_PC5	Fifth MO PC in retrolenticular part of internal capsule	Diffusion MR
mo.pheno76	MO_SCC_PC1	First MO PC in the splenium of corpus callosum	Diffusion MR
mo.pheno77	MO_SCC_PC2	Second MO PC in the splenium of corpus callosum	Diffusion MR
mo.pheno78	MO_SCC_PC3	Third MO PC in the splenium of corpus callosum	Diffusion MR
mo.pheno79	MO_SCC_PC4	Fourth MO PC in the splenium of corpus callosum	Diffusion MR
mo.pheno80	MO_SCC_PC5	Fifth MO PC in the splenium of corpus callosum	Diffusion MR
mo.pheno81	MO_SCR_PC1	First MO PC in the superior corona radiata	Diffusion MR
mo.pheno82	MO_SCR_PC2	Second MO PC in the superior corona radiata	Diffusion MR
mo.pheno83	MO_SCR_PC3	Third MO PC in the superior corona radiata	Diffusion MR
mo.pheno84	MO_SCR_PC4	Fourth MO PC in the superior corona radiata	Diffusion MR
mo.pheno85	MO_SCR_PC5	Fifth MO PC in the superior corona radiata	Diffusion MR
mo.pheno86	MO_SFO_PC1	First MO PC in the superior fronto-occipital fasciculus	Diffusion MR
mo.pheno87	MO_SFO_PC2	Second MO PC in the superior fronto-occipital fasciculus	Diffusion MR
mo.pheno88	MO_SFO_PC3	Third MO PC in the superior fronto-occipital fasciculus	Diffusion MR
mo.pheno89	MO_SFO_PC4	Fourth MO PC in the superior fronto-occipital fasciculus	Diffusion MR
mo.pheno90	MO_SFO_PC5	Fifth MO PC in the superior fronto-occipital fasciculus	Diffusion MR
mo.pheno91	MO_SLF_PC1	First MO PC in the superior longitudinal fasciculus	Diffusion MR
mo.pheno92	MO_SLF_PC2	Second MO PC in the superior longitudinal fasciculus	Diffusion MR
mo.pheno93	MO_SLF_PC3	Third MO PC in the superior longitudinal fasciculus	Diffusion MR
mo.pheno94	MO_SLF_PC4	Fourth MO PC in the superior longitudinal fasciculus	Diffusion MR
mo.pheno95	MO_SLF_PC5	Fifth MO PC in the superior longitudinal fasciculus	Diffusion MR
mo.pheno96	MO_SS_PC1	First MO PC in sagittal stratum	Diffusion MR
mo.pheno97	MO_SS_PC2	Second MO PC in sagittal stratum	Diffusion MR
mo.pheno98	MO_SS_PC3	Third MO PC in sagittal stratum	Diffusion MR
mo.pheno99	MO_SS_PC4	Fourth MO PC in sagittal stratum	Diffusion MR
mo.pheno100	MO_SS_PC5	Fifth MO PC in sagittal stratum	Diffusion MR
mo.pheno101	MO_UNC_PC1	First MO PC in uncinate fasciculus	Diffusion MR
mo.pheno102	MO_UNC_PC2	Second MO PC in uncinate fasciculus	Diffusion MR
mo.pheno103	MO_UNC_PC3	Third MO PC in uncinate fasciculus	Diffusion MR
mo.pheno104	MO_UNC_PC4	Fourth MO PC in uncinate fasciculus	Diffusion MR
mo.pheno105	MO_UNC_PC5	Fifth MO PC in uncinate fasciculus	Diffusion MR

(Cont'd...)

Table S1. (Continued)

ID	Phenocode	Meaning	Classification
rd.pheno1	RD_ACR_PC1	First RD PC in the anterior corona radiata	Diffusion MR
rd.pheno2	RD_ACR_PC2	Second RD PC in the anterior corona radiata	Diffusion MR
rd.pheno3	RD_ACR_PC3	Third RD PC in the anterior corona radiata	Diffusion MR
rd.pheno4	RD_ACR_PC4	Fourth RD PC in the anterior corona radiata	Diffusion MR
rd.pheno5	RD_ACR_PC5	Fifth RD PC in the anterior corona radiata	Diffusion MR
rd.pheno6	RD_ALIC_PC1	First RD PC in the anterior limb of internal capsule	Diffusion MR
rd.pheno7	RD_ALIC_PC2	Second RD PC in the anterior limb of internal capsule	Diffusion MR
rd.pheno8	RD_ALIC_PC3	Third RD PC in the anterior limb of internal capsule	Diffusion MR
rd.pheno9	RD_ALIC_PC4	Fourth RD PC in the anterior limb of internal capsule	Diffusion MR
rd.pheno10	RD_ALIC_PC5	Fifth RD PC in the anterior limb of internal capsule	Diffusion MR
rd.pheno11	RD_BCC_PC1	First RD PC in body of corpus callosum	Diffusion MR
rd.pheno12	RD_BCC_PC2	Second RD PC in body of corpus callosum	Diffusion MR
rd.pheno13	RD_BCC_PC3	Third RD PC in body of corpus callosum	Diffusion MR
rd.pheno14	RD_BCC_PC4	Fourth RD PC in body of corpus callosum	Diffusion MR
rd.pheno15	RD_BCC_PC5	Fifth RD PC in body of corpus callosum	Diffusion MR
rd.pheno16	RD_CGC_PC1	First RD PC in cingulum (cingulate gyrus)	Diffusion MR
rd.pheno17	RD_CGC_PC2	Second RD PC in cingulum (cingulate gyrus)	Diffusion MR
rd.pheno18	RD_CGC_PC3	Third RD PC in cingulum (cingulate gyrus)	Diffusion MR
rd.pheno19	RD_CGC_PC4	Fourth RD PC in cingulum (cingulate gyrus)	Diffusion MR
rd.pheno20	RD_CGC_PC5	Fifth RD PC in cingulum (cingulate gyrus)	Diffusion MR
rd.pheno21	RD_CGH_PC1	First RD PC in cingulum (hippocampus)	Diffusion MR
rd.pheno22	RD_CGH_PC2	Second RD PC in cingulum (hippocampus)	Diffusion MR
rd.pheno23	RD_CGH_PC3	Third RD PC in cingulum (hippocampus)	Diffusion MR
rd.pheno24	RD_CGH_PC4	Fourth RD PC in cingulum (hippocampus)	Diffusion MR
rd.pheno25	RD_CGH_PC5	Fifth RD PC in cingulum (hippocampus)	Diffusion MR
rd.pheno26	RD_CST_PC1	First RD PC in corticospinal tract	Diffusion MR
rd.pheno27	RD_CST_PC2	Second RD PC in corticospinal tract	Diffusion MR
rd.pheno28	RD_CST_PC3	Third RD PC in corticospinal tract	Diffusion MR
rd.pheno29	RD_CST_PC4	Fourth RD PC in corticospinal tract	Diffusion MR
rd.pheno30	RD_CST_PC5	Fifth RD PC in corticospinal tract	Diffusion MR
rd.pheno31	RD_EC_PC1	First RD PC in external capsule	Diffusion MR
rd.pheno32	RD_EC_PC2	Second RD PC in external capsule	Diffusion MR
rd.pheno33	RD_EC_PC3	Third RD PC in external capsule	Diffusion MR
rd.pheno34	RD_EC_PC4	Fourth RD PC in external capsule	Diffusion MR
rd.pheno35	RD_EC_PC5	Fifth RD PC in external capsule	Diffusion MR
rd.pheno36	RD_FX_PC1	First RD PC in fornix (column and body of fornix)	Diffusion MR
rd.pheno37	RD_FX_PC2	Second RD PC in fornix (column and body of fornix)	Diffusion MR
rd.pheno38	RD_FX_PC3	Third RD PC in fornix (column and body of fornix)	Diffusion MR
rd.pheno39	RD_FX_PC4	Fourth RD PC in fornix (column and body of fornix)	Diffusion MR
rd.pheno40	RD_FX_PC5	Fifth RD PC in fornix (column and body of fornix)	Diffusion MR
rd.pheno41	RD_FXST_PC1	First RD PC in fornix-stria terminalis	Diffusion MR
rd.pheno42	RD_FXST_PC2	Second RD PC in fornix-stria terminalis	Diffusion MR

(Cont'd...)

Table S1. (Continued)

ID	Phenocode	Meaning	Classification
rd.pheno43	RD_FXST_PC3	Third RD PC in fornix-stria terminalis	Diffusion MR
rd.pheno44	RD_FXST_PC4	Fourth RD PC in fornix-stria terminalis	Diffusion MR
rd.pheno45	RD_FXST_PC5	Fifth RD PC in fornix-stria terminalis	Diffusion MR
rd.pheno46	RD_GCC_PC1	First RD PC in genu of corpus callosum	Diffusion MR
rd.pheno47	RD_GCC_PC2	Second RD PC in genu of corpus callosum	Diffusion MR
rd.pheno48	RD_GCC_PC3	Third RD PC in genu of corpus callosum	Diffusion MR
rd.pheno49	RD_GCC_PC4	Fourth RD PC in genu of corpus callosum	Diffusion MR
rd.pheno50	RD_GCC_PC5	Fifth RD PC in genu of corpus callosum	Diffusion MR
rd.pheno51	RD_IFO_PC1	First RD PC in the inferior fronto-occipital fasciculus	Diffusion MR
rd.pheno52	RD_IFO_PC2	Second RD PC in the inferior fronto-occipital fasciculus	Diffusion MR
rd.pheno53	RD_IFO_PC3	Third RD PC in the inferior fronto-occipital fasciculus	Diffusion MR
rd.pheno54	RD_IFO_PC4	Fourth RD PC in the inferior fronto-occipital fasciculus	Diffusion MR
rd.pheno55	RD_IFO_PC5	Fifth RD PC in the inferior fronto-occipital fasciculus	Diffusion MR
rd.pheno56	RD_PCR_PC1	First RD PC in the posterior corona radiata	Diffusion MR
rd.pheno57	RD_PCR_PC2	Second RD PC in the posterior corona radiata	Diffusion MR
rd.pheno58	RD_PCR_PC3	Third RD PC in the posterior corona radiata	Diffusion MR
rd.pheno59	RD_PCR_PC4	Fourth RD PC in the posterior corona radiata	Diffusion MR
rd.pheno60	RD_PCR_PC5	Fifth RD PC in the posterior corona radiata	Diffusion MR
rd.pheno61	RD_PLIC_PC1	First RD PC in the posterior limb of internal capsule	Diffusion MR
rd.pheno62	RD_PLIC_PC2	Second RD PC in the posterior limb of internal capsule	Diffusion MR
rd.pheno63	RD_PLIC_PC3	Third RD PC in the posterior limb of internal capsule	Diffusion MR
rd.pheno64	RD_PLIC_PC4	Fourth RD PC in the posterior limb of internal capsule	Diffusion MR
rd.pheno65	RD_PLIC_PC5	Fifth RD PC in the posterior limb of internal capsule	Diffusion MR
rd.pheno66	RD_PTR_PC1	First RD PC in the posterior thalamic radiation	Diffusion MR
rd.pheno67	RD_PTR_PC2	Second RD PC in the posterior thalamic radiation	Diffusion MR
rd.pheno68	RD_PTR_PC3	Third RD PC in the posterior thalamic radiation	Diffusion MR
rd.pheno69	RD_PTR_PC4	Fourth RD PC in the posterior thalamic radiation	Diffusion MR
rd.pheno70	RD_PTR_PC5	Fifth RD PC in the posterior thalamic radiation	Diffusion MR
rd.pheno71	RD_RLIC_PC1	First RD PC in retrolenticular part of internal capsule	Diffusion MR
rd.pheno72	RD_RLIC_PC2	Second RD PC in retrolenticular part of internal capsule	Diffusion MR
rd.pheno73	RD_RLIC_PC3	Third RD PC in retrolenticular part of internal capsule	Diffusion MR
rd.pheno74	RD_RLIC_PC4	Fourth RD PC in retrolenticular part of internal capsule	Diffusion MR
rd.pheno75	RD_RLIC_PC5	Fifth RD PC in retrolenticular part of internal capsule	Diffusion MR
rd.pheno76	RD_SCC_PC1	First RD PC in the splenium of corpus callosum	Diffusion MR
rd.pheno77	RD_SCC_PC2	Second RD PC in the splenium of corpus callosum	Diffusion MR
rd.pheno78	RD_SCC_PC3	Third RD PC in the splenium of corpus callosum	Diffusion MR
rd.pheno79	RD_SCC_PC4	Fourth RD PC in the splenium of corpus callosum	Diffusion MR
rd.pheno80	RD_SCC_PC5	Fifth RD PC in the splenium of corpus callosum	Diffusion MR
rd.pheno81	RD_SCR_PC1	First RD PC in the superior corona radiata	Diffusion MR
rd.pheno82	RD_SCR_PC2	Second RD PC in the superior corona radiata	Diffusion MR
rd.pheno83	RD_SCR_PC3	Third RD PC in the superior corona radiata	Diffusion MR
rd.pheno84	RD_SCR_PC4	Fourth RD PC in the superior corona radiata	Diffusion MR

(Cont'd...)

Table S1. (Continued)

ID	Phenocode	Meaning	Classification
rd.pheno85	RD_SCR_PC5	Fifth RD PC in the superior corona radiata	Diffusion MR
rd.pheno86	RD_SFO_PC1	First RD PC in the superior fronto-occipital fasciculus	Diffusion MR
rd.pheno87	RD_SFO_PC2	Second RD PC in the superior fronto-occipital fasciculus	Diffusion MR
rd.pheno88	RD_SFO_PC3	Third RD PC in the superior fronto-occipital fasciculus	Diffusion MR
rd.pheno89	RD_SFO_PC4	Fourth RD PC in the superior fronto-occipital fasciculus	Diffusion MR
rd.pheno90	RD_SFO_PC5	Fifth RD PC in the superior fronto-occipital fasciculus	Diffusion MR
rd.pheno91	RD_SLF_PC1	First RD PC in the superior longitudinal fasciculus	Diffusion MR
rd.pheno92	RD_SLF_PC2	Second RD PC in the superior longitudinal fasciculus	Diffusion MR
rd.pheno93	RD_SLF_PC3	Third RD PC in the superior longitudinal fasciculus	Diffusion MR
rd.pheno94	RD_SLF_PC4	Fourth RD PC in the superior longitudinal fasciculus	Diffusion MR
rd.pheno95	RD_SLF_PC5	Fifth RD PC in the superior longitudinal fasciculus	Diffusion MR
rd.pheno96	RD_SS_PC1	First RD PC in sagittal stratum	Diffusion MR
rd.pheno97	RD_SS_PC2	Second RD PC in sagittal stratum	Diffusion MR

Note: The WM IDPs summary statistics were derived from the UK Biobank British cohort, consisting of 33,292 samples.

Abbreviations: ACR: Anterior corona radiata; ALIC: Anterior limb of internal capsule; BCC: Body of corpus callosum; CGC: Cingulum (cingulate gyrus); CGH: Cingulum (hippocampus); CST: Corticospinal tract; EC: External capsule; FX: Fornix (column and body of fornix); FXST: Fornix-stria terminalis; GCC: Genu of corpus callosum; IDP: Imaging-derived phenotype; IFO: Inferior fronto-occipital fasciculus; MO: Mode of anisotropy; PC: Principal component; PCR: Posterior corona radiata; PLIC: Posterior limb of internal capsule; PTR: Posterior thalamic radiation; RD: Radial diffusivity; RLIC: Retrolenticular part of internal capsule; SCC: Splenium of corpus callosum; SCR: Superior corona radiata; SFO: Superior fronto-occipital fasciculus; SLF: Superior longitudinal fasciculus; SS: Sagittal stratum; UNC: Uncinate fasciculus; WM: White matter.