



TECHNICAL REPORT

Modified transapical-transcatheter aortic valve implantation

Dritan Useini^{1,2*}, Justus Strauch¹¹Department of Cardiothoracic Surgery, Ruhr-University Hospital Bergmannsheil, Bochum, Germany, ²Department of Cardiovascular Surgery, Herz-Kreislauf-Zentrum, Rotenburg a. d. Fulda, Germany

ARTICLE INFO

Article history:

Received: May 29, 2022

Revised: June 11, 2022

Accepted: July 7, 2022

Published online: July 25, 2022

Keywords:

novelty

modified

transapical-transcatheter aortic valve implantation

end-stage panarteriopathy

*Corresponding author:

Dritan Useini, Department of Cardiothoracic Surgery, Ruhr-University Hospital Bergmannsheil, Bochum, Germany; Department of Cardiovascular Surgery, Herz-Kreislauf-Zentrum, Rotenburg a. d. Fulda, Germany. E-mail: dritan-83@live.com

© 2022 Author(s). This is an Open-Access article distributed under the terms of the Creative Commons Attribution-Noncommercial License, permitting all non-commercial use, distribution, and reproduction in any medium, provided the original work is properly cited.

Abstract

Background and Aim: Some transcatheter aortic valve implantation (TAVI) candidates present with ubiquitary arterial disease with massive calcification burden and stenoses in the whole arterial tree and cannot undergo any transvascular TAVI-approach. Moreover, a history of previous coronary surgery including LIMA-LITA *in situ* bypass grafting, previous carotid surgery or stenosis/occlusions, a concomitant porcelain aorta, Leriche syndrome, diverse other aortic diseases, arterial occlusions, or a chronic dialysis with arteriovenous shunt are common in such patients with end-stage peripheral artery disease, making even a minimal artery access impossible. For patients without arterial access or at very high risk for artery injury, we modified the transapical-TAVI method to ensure artery-no-touch-technique. We employed this technique in six patients without procedural and in-hospital complications. **Relevance for Patients:** A high-grade aortic stenosis is a serious disease. Untreated patients exhibit poor survival. Only surgery or TAVI is valid therapy concept for treatment. However, some patients can undergo neither surgery nor TAVI, because of an extensive surgical risk or inoperability, whereas at the same time, no arterial approaches are available due to extensive, end-stage panarteriopathy. For these high-specific patients, our modified, artery-no-touch-TA-TAVI is an appropriate method and can be safely used.

1. Introduction

Some transcatheter aortic valve implantation (TAVI) candidates present with clinical characteristics who cannot undergo transfemoral-TAVI. As consequence, other alternative transvascular approaches, such as transcarotid or transsubclavian, have been studied and preferred for this specific TAVI-population [1-3]. However, data on multimorbid and high-risk patients with severe aortic stenosis who cannot undergo transfemoral-TAVI and at the same time exhibit concomitant femoral-remote severe arteriopathies (i.e., carotid/subclavian arteriopathies), precluding an eventual use of the transcarotid or the transsubclavian approach are lacking. The prevalence of this specific and high-risk group of patients within TAVI candidates is unknown. Moreover, treatment options and clinical outcomes are unclear. Therefore, we previously studied patients with panarteriopathy undergoing transapical (TA)-TAVI [4]. For patients with end-stage panarteriopathy, we modified the TA-TAVI method to ensure artery-no-touch-technique [4]. We aimed in this technical report to highlight in detail all crucial technical steps of our modified TA-TAVI.

2. Technique Description

The TA-TAVI procedure has been described previously step-by-step by Walther *et al.* [5]. We describe here our crucial modified steps of the TA-TAVI procedure for patients with zero arterial access.

1. Insertion of a femoral vein wire to serve as a “safety net” was performed and at the same time the insertion of an artery wire, a 6-French sheath, and a line (pigtail) through any artery was disclaimed (Figure 1).
2. To minimize apex trauma, a soft guidewire was inserted antegrade across the stenotic aortic and was not followed by the insertion of a 14-French soft-tip sheath for positioning of a stiff guidewire. Instead, a 6-French sheath was used (Figure 2).
3. Balloon aortic valvuloplasty was not used.
4. The insertion of the “artery wire,” a 6-French sheath, and a line (pigtail) as “safety net” and for angiographic visualization were performed through the left ventricle wall, approximately 1 cm beside the valve delivery sheath, and the pigtail was introduced through the native aortic valve into the ascending aorta (Figure 3).
5. Before completing the valve expansion (in the “dogboning” position), the pigtail was placed back into the left ventricle, and after complete valve expansion again into the ascending aorta through the valve prosthesis for quality control (Figure 4).

3. Discussion

We favored in this work explaining only the modified steps to avoid unnecessary emphasizing of already known steps of the procedure. We sought with this piece of work to clarify procedural details, which may facilitate implementation of the technique from other interventionists. The procedures were performed under general anesthesia using a minimally invasive left anterolateral thoracotomy measuring 6–7 cm wound length. Although the whole procedure was performed through the apex, there was no need for longer skin incision in this modified setting. The only two purse-string myocardial sutures are sufficient to close the apex wound after valve implantation. The angiographic visualization should be performed with a pigtail with low number of side holes positioned in the apical parts to minimize contrast media application and to avoid left ventricle filling with contrast media.

Two crucial moments of our modified TA-TAVI are of high importance to avoid bleeding, life-threatening blood lost, or myocardial injury: (1) The avoidance of the insertion of a 14-French soft-tip sheath through the ventricle wall after wire insertion and (2) the avoidance of the balloon aortic valvuloplasty.

Placing a 6-French sheath in addition to the valve delivery sheath was not associated with higher myocardial trauma or bleeding complications in our cases. Any catheter interference was not registered. Before valve expansion, the pigtail can be easily placed back into the left ventricle, during “dogboning,” and thereafter again into the ascending aorta through the valve prosthesis to evaluate coronary perfusion, valve position, and an eventual paravalvular leak.

As it is clear that some patients cannot undergo transfemoral approach [6], one of the most recent themes in the “TAVI-World” are alternative transvascular TAVI approaches [1-3]. However, patients with iliofemoral and concomitant iliofemoral-

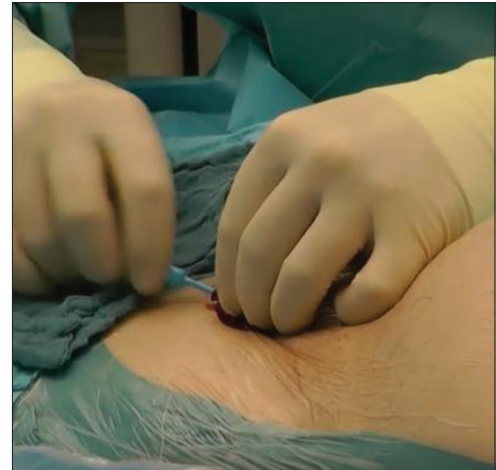

Figure 1. Insertion of a femoral vein wire to serve as a “safety net”.

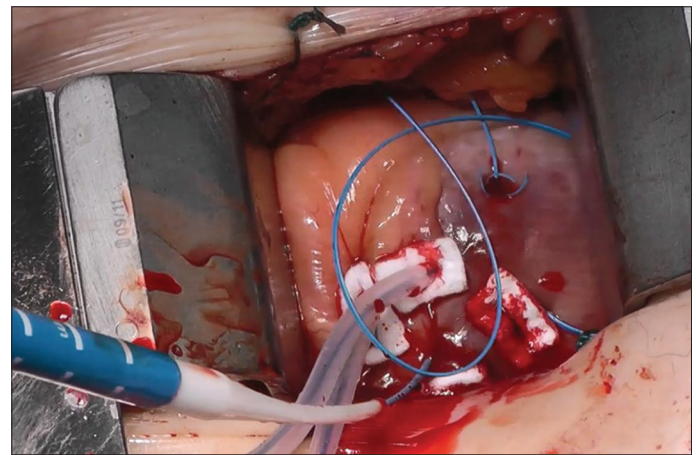


Figure 2. First 6-French sheath was used for positioning of a stiff guidewire and valve delivery sheath.

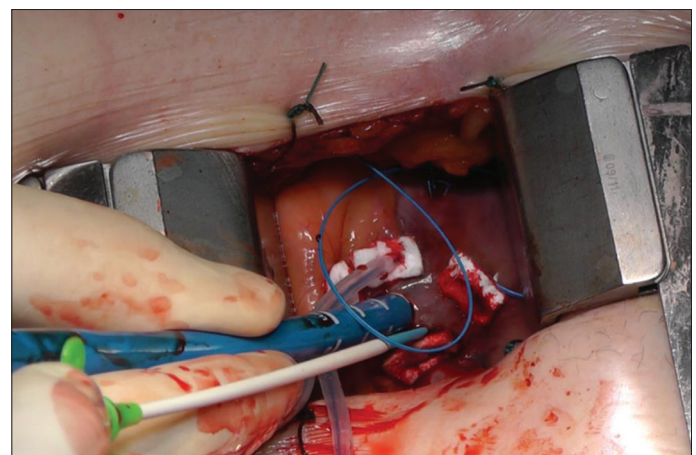


Figure 3. Second 6-French sheath, and a line (pigtail) as “safety net” and for angiographic visualization were performed through the left ventricle wall, approximately 1 cm beside the valve delivery sheath.

remote arteriopathies who cannot undergo transfemoral and other alternative transvascular approaches have not been studied

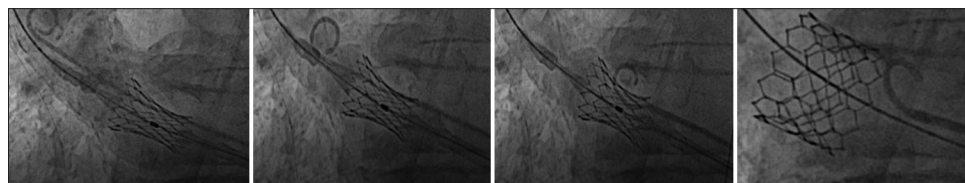


Figure 4. Final visualization of the aortic root, “dogboning” of the prosthesis and positioning of the pigtail into the left ventricle for fully prosthesis expansion.

so far [4]. Further, high surgical risk patients without any arterial access who require TAVI can be expected in the clinical praxis. Typical patients are they with severe aortopathies and extensive peripheral artery disease. Some of these patients have occluded arteries of brachiocephalic artery tree or a history of previous surgery or intervention. An arteriovenous shunt for dialysis or a previous coronary surgery including LIMA-LITA *in situ* bypass grafting may be further limiting circumstances [7]. Therefore, we modified the TA-TAVI to artery-no-touch-technique.

It is nowadays a fact that alternative transvascular approaches such as transsubclavian or transcarotid are “on the rise” and have been emerged as most preferred approaches for patients who cannot undergo transfemoral TAVI [1-3]. However, it is remarkable that studies on alternative transvascular approaches seem to avoid facing the issue of an eventual need for circulatory support in case of a cardiogenic shock during TAVI [1-3], in which case immediate establishment of an extracorporeal-life-support-system (ECLS) is of paramount importance. In patients who cannot undergo transfemoral TAVI and undergo alternative transvascular approaches, femoral access for ECLS is precluded due to severe pathologies of femoral arteries.

The modified TA-TAVI offers a unique possibility to artery-no-touch-technique ECLS implantation, as well. This can be achieved through the heart apex and the femoral vein.

4. Conclusion

Our modified TA-TAVI can be used in high-risk patients with severe aortic stenosis with end-stage severe panarteriopathy with zero arterial access who cannot undergo any transvascular approach. At the same time, this mode offers possibility to establish ECLS if necessary.

4.1. Limitations of the procedure

Some clinical scenarios may appear as a limitation for conduction of this new technique. In patients with the left ventricle thrombus or a huge aneurysm of the left ventricle, this novel technique should not be performed, to avoid potential thrombus embolization or life-threatening bleeding, respectively. Further, a fresh myocardial infarction involving the left anterior descending coronary artery area of vascularization may be risky with respect to the apex bleeding immediately after the procedure or a potential development of an apex aneurysm on long-term. The potential risks that the operators should pay special attention to are apex injury with potential acute bleeding and rib fracture causing post-operative pain and bleeding.

Acknowledgments

None.

Funding

None.

Conflict of Interest

The authors declare no conflict of interest.

References

- [1] Dahle TG, Kaneko T, McCabe JM. Outcomes Following Subclavian and Axillary Artery Access for Transcatheter Aortic Valve Replacement: Society of the Thoracic Surgeons/American College of Cardiology TVT Registry Report. *JACC Cardiovasc Interv.* 2019;12:662-9.
- [2] Kirker E, Korngold E, Hodson RW, Jones BM, McKay R, Cheema M, *et al.* Transcarotid vs Subclavian/Axillary Access for Transcatheter Aortic Valve Replacement with SAPIEN 3. *Ann Thorac Surg* 2020;110:1892-7.
- [3] Debry N, Trimech TR, Gandet T, Vincent F, Hysi I, Delhay C, *et al.* Transaxillary Compared with Transcarotid Access for TAVR: A Propensity-matched Comparison from a French Multicentre Registry. *EuroIntervention* 2020;16:842-9.
- [4] Useini D, Schlömacher M, Haldenwang P, Buchwald D, Strauch J. Transapical-transcatheter Aortic Valve Implantation in Patients Without Transvascular Options: Modified Transapical Approach. *J Card Surg* 2022;37:1635-41.
- [5] Walther T, Dewey T, Borger MA, Kempfert J, Linke A, Becht R, *et al.* Transapical aortic valve implantation: Step by Step. *Ann Thorac Surg* 2009;87:276-83.
- [6] Kindzelski B, Mick SL, Krishnaswamy A, Kapadia SR, Attia T, Hodges K, *et al.* Evolution of Alternative Access Transcatheter Aortic Valve Replacement. *Ann Thorac Surg* 2021;112:1877-85.
- [7] Useini D, Beluli B, Christ H, Schlömacher M, Ewais E, Patsalis P, *et al.* Transapical transcatheter aortic valve implantation in patients with aortic diseases. *Eur J Cardiothorac Surg* 2021;59:1174-81.

Publisher's note

Whioce Publishing remains neutral with regard to jurisdictional claims in published maps and institutional affiliations.